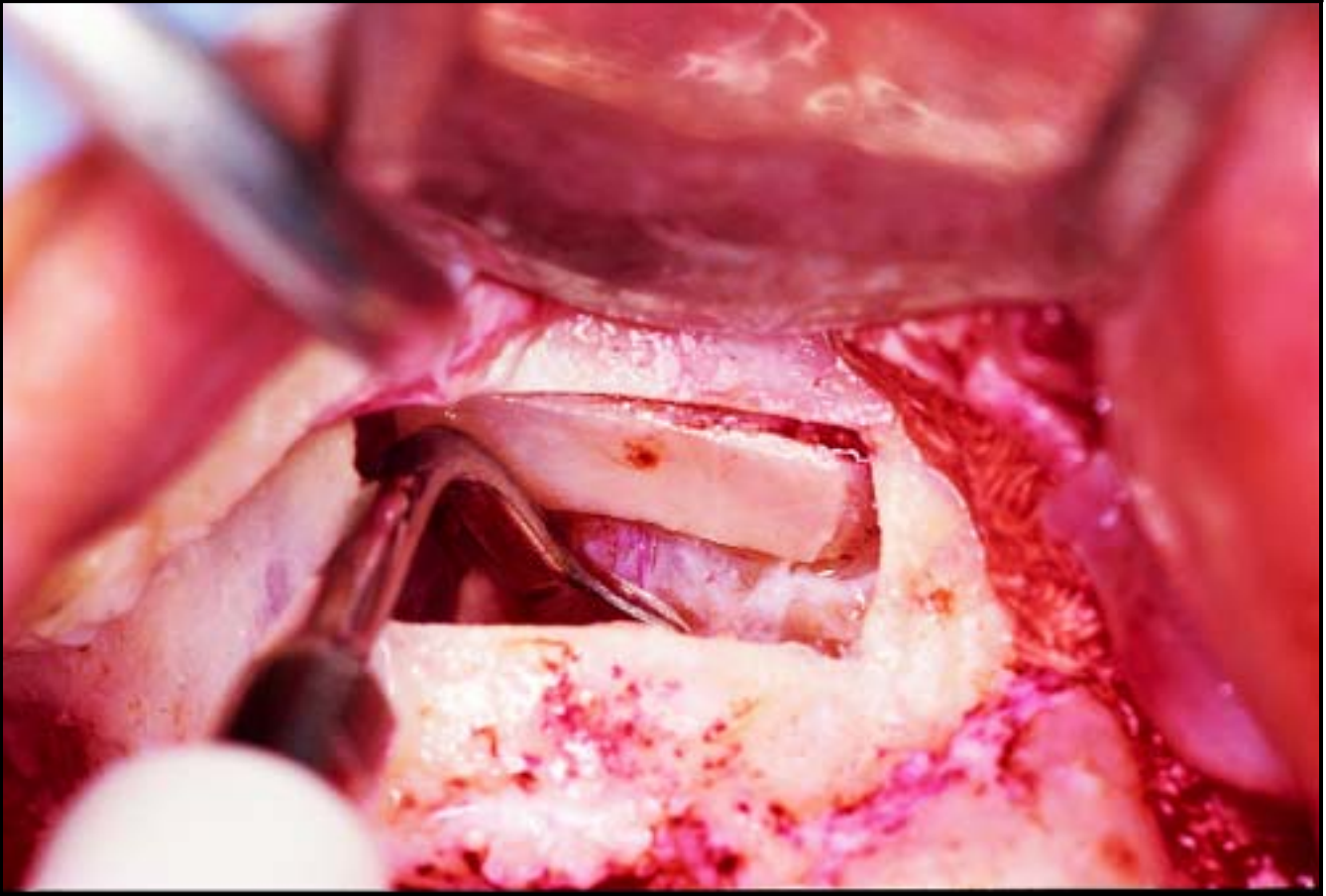
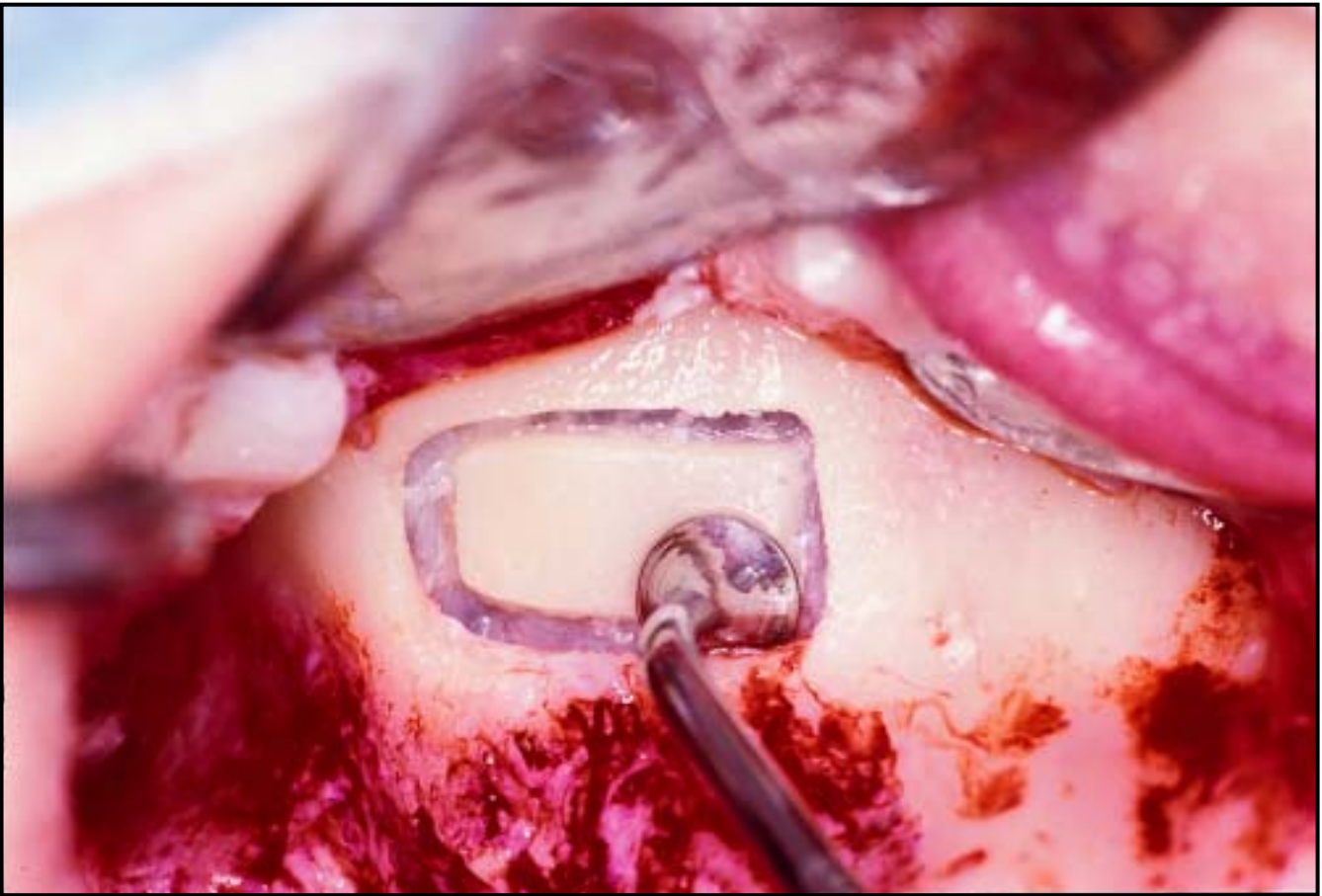
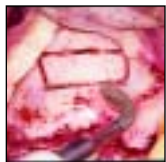The Piezoelectric Bony Window Osteotomy and Sinus Membrane Elevation: Introduction of a New Technique for Simplification of the Sinus Augmentation Procedure



Tomaso Vercellotti, MD, DDS*
Sergio De Paoli, MD, DDS**
Myron Nevins, DDS***

All of the surgical techniques to elevate the maxillary sinus present the possibility of perforating the schneiderian membrane. This complication can occur during the osteotomy, which is performed with burs, or during the elevation of the membrane using manual elevators. The purpose of this article is to present a new surgical technique that radically simplifies maxillary sinus surgery, thus avoiding perforating the membrane. The piezoelectric bony window osteotomy easily cuts mineralized tissue without damaging the soft tissue, and the piezoelectric sinus membrane elevation separates the schneiderian membrane without causing perforations. The elevation of the membrane from the sinus floor is performed using both piezoelectric elevators and the force of a physiologic solution subjected to piezoelectric cavitation. Twenty-one piezoelectric bony window osteotomy and piezoelectric sinus membrane elevations were performed on 15 patients using the appropriate surgical device (Mectron Piezosurgery System). Only one perforation occurred during the osteotomy at the site of an underwood septa, resulting in a 95% success rate. The average length of the window was 14 mm; its height was 6 mm, and its thickness was 1.4 mm. The average time necessary for the piezoelectric bony window osteotomy was approximately 3 minutes, while the piezoelectric sinus membrane elevation required approximately 5 minutes. (Int J Periodontics Restorative Dent 2001;21:561–567.)

*Private Practice, Genova and Merano, Italy.

**Private Practice, Ancona and Rome, Italy.

***Clinical Associate Professor of Periodontology, Harvard School of Dental Medicine, Boston, Massachusetts.

Reprint requests: Dr Tomaso Vercellotti, Via XII Ottobre 2/111, 16121 Genova, Italy. e-mail: tovercel@tin.it

Various studies prove the high success rate of prosthetic rehabilitation with implants of the upper posterior maxilla. In the presence of normal bone volume and density,^{1–3} the standard surgical technique consists of a simple preparation of the implant site and results in a success rate of almost 100%, with rare and easily solved postsurgical complications.^{4,5}

However, when the upper maxilla is atrophied in the posterior area, the residual crest is insufficient to serve as an implant site.^{6,7} The most effective surgical method to solve these anatomically unfavorable conditions is therefore found in an advanced surgical technique that elevates the floor of the maxillary sinus by means of a bone sinus graft to obtain a properly sized implant site in the cavity (the sinus augmentation procedure).⁸ The most common surgical technique to access the maxillary sinus opens a bony window in the lateroposterior wall using a modified version of the Caldwell-Luc osteotomy technique.^{9–13} The most important factor is to keep the schneiderian membrane intact so

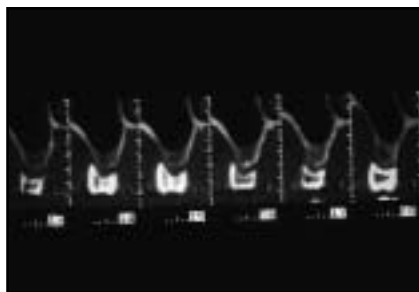


Fig 1 Each patient underwent CT examination with a diagnostic paraxial stent. This made it possible to determine the correct position of the bony window and measure the thickness of the lateral sinus walls.

that once lifted, it can become the recipient site for the bone graft and stabilize the graft during the healing period.

The limits of this technique include the possibility of accidentally perforating the membrane, either with the burs during the osteotomy or with the manual elevators during the separation of the membrane. It is of great importance that the membrane remain intact during the first stage of the healing of the graft, guaranteeing stability and therefore allowing vascularization that will lead to the maturation and mineralization of the bone. If the membrane perforation is small, it is usually surgically solvable if the surgeon is prepared to repair the membrane and risk the possible complications.¹⁴ Often, however, a small perforation made by the burs can be accidentally enlarged by the elevators during the elevation stage because of the presence of adhesions, which can produce a large lesion that forces surgery to be delayed.

If the bone graft is carried out in the case of a membrane lesion, it is very likely that parts of the bone graft will go to an ectopic site, usually on the surface of the respiratory mucous epithelium; this would entail the necrosis of the graft, followed by a suppurative process in the sinus cavity, generally visible in the orosinus antral fistula. In other words, advanced implant surgery following this complication can cause a notable morbidity for the patient. For this reason, many surgeons who place implants do not routinely use the sinus augmentation procedure.

The purpose of this study is to present a new surgical technique, the piezoelectric bony window osteotomy and sinus membrane elevation (PBWO and PSME), that radically simplifies surgery to the maxillary sinus, reducing the possibility of postoperative complications and making the results comparable to those obtained using a standard implant technique. This new technique^{15,16} uses a specifically engineered device (Mectron Piezosurgery System) to perform the osteotomy.

The advantage of the piezoelectric osteotomy consists of cutting the bony window with great simplicity and precision, avoiding the risk of perforating the membrane thanks to the shape of the bone scalpels working with ultrasonic modulating vibrations. This is due to the cessation of the surgical action when the scalpel comes into contact with nonmineralized tissue. The subsequent use of the piezoelectric elevators lifts the membrane without

heightened risk of perforation, even in anatomically complex situations. The separation of the endosteum from the flat bone is achieved by the ultrasonic vibrations of the piezoelectric elevator working on the internal part of the sinus bone walls and by hydropneumatic pressure of a physiologic solution subjected to piezoelectric cavitation.

Method and materials

Twenty-one PBWO and PSME procedures were performed on 15 patients; six underwent a bilateral sinus augmentation procedure and nine had a monolateral procedure. All of the patients were edentulous in the posterior maxilla, with a residual bone crest of approximately 4 mm. The mean patient age was 56 years; 54% were men, and 54% were nonsmokers.

Every patient underwent a presurgical study consisting of their medical history, dental history, habit history, blood test, and a computed tomographic (CT) examination with a diagnostic stent to determine the height of the residual crestal bone and consequently the position and dimension of the bony window (Fig 1). It was ascertained that there was no sinus pathology. The CT examination determined the average thickness of the sinus lateral wall (Table 1). All patients were informed of the therapeutic alternatives to the sinus lift and of the risk of perforating the sinus membrane, a possible complication of the operation

Table 1 Patient details and window measurements

Patient	Age (y)	Sex	Smoker	Height of window (mm)	Length of window (mm)	Thickness of window (mm)	Osteotomy time (min)	Membrane elevation time (min)
RM	57	F	No	6	15	1.0	2	4
PD left	54	F	Yes	5	13	1.0	4	7
PD right				6	15		2	5
BD left	41	M	No	7	18	2.0	3	6
BD right				5	13		3	4
BG	51	M	Yes	6	16	1.0	2	5
PF	52	F	No	7	13	1.5	4	4
LC left	54	F	No	7	14	2.0	2	4
LC right				6	16		4	5
VG	54	F	Yes	7	15	1.0	3	8
GF	51	M	Yes	5	16	1.5	4	6
DZ	52	F	No	6	15	1.0	3	4
ZL	56	F	No	8	16	2.0	3	5
GR left	50	M	No	8	15	2.0	2	5
GR right				5	14		2	
AC	65	M	Yes	5	7	1.0	2	6
CA	55	M	Yes	7	14	1.0	3	7
SV left	42	M	No	7	16	1.5	5	6
SV right				6			3	5
MG* left	55	M	Yes	6	16	1.0	2	7
MG* right				7	15		4	6

*Perforation.

(especially in smokers). Informed consent was obtained from all.

The Mectron Piezosurgery System consists of a platform with a very powerful piezoelectric handpiece with a functional frequency of 25 to 29 kHz and the possibility of a digital modulation of 30 Hz. There are four sinus lift surgical inserts: diamond scalpel, conical compressor, and two differently shaped elevators. The inserts move with a linear vibration of between 60 and 210 μ m, providing the handpiece with power exceeding 5 W and a high-powered pump that emits the physiologic solution.

Surgical procedure

With the blade of the 15c scalpel, a horizontal crestal incision was made at the top of the ridge from the distal aspect of the maxilla, continuing mesially until it reached one or two of the anterior teeth, where a vertical releasing incision was made. Another releasing incision was made in the distal aspect under the parotidian duct. A flap of the total vestibular thickness was raised; it was characterized by a broad vascular supply mesially and distally. The most apical parts of the two incisions were united by a horizontal

periosteal incision to give greater elasticity to the mucous flap in the suturing phase.

Piezoelectric bony window osteotomy

To open the sinus window, the following surgical procedure was carried out. With the No. 1 scalpel from the Sinus Lift system by Mectron Piezosurgery, an outline was drawn. It began with the most coronal horizontal incision, with a length of approximately 14 mm positioned approximately 3 mm apical to the

residual crestal bone. Two vertical incisions of 6 to 7 mm were made and united at the top by another horizontal incision. The bony window was performed in the area of the second premolar–first molar (Fig 2). In only three cases was it drawn more mesially in the first premolar area. The outline was drawn in about 3 minutes, and the average thickness of the cut was approximately 1 mm. This produced a bony window in which the frame is represented by the schneiderian membrane (sometimes red in color, sometimes blue; Fig 3). At this point, the osteotomy was completed by rounding the angles of the window.

Piezoelectric sinus membrane elevation

The No. 2 insert, a compressor in the shape of an overturned cone, was inserted into the edge of the frame of the membrane exposed by the osteotomy. It separated the borders approximately 2 mm with ease (Fig 4). At this point, the No. 3 insert (an angled periosteal elevator with rounded edges; Fig 5) or the No. 4 (a straight periosteal elevator), depending on the anatomic situation, was used in the following order.

The first stage of the membrane elevation begins in the apical position (Fig 6). The membrane separation in the apical direction depends on the length of the implants that will be placed in the second surgery. The insert is directed toward the mesial surface, separating the membrane until it meets the anterior walls of

the sinus. The insert is then directed toward the distal walls, separating the membrane to obtain the volume required for the graft to build the future implant site. Finally, the insert is directed toward the crestal position, where it is possible to meet adhesions, particularly in the depths of the molar depressions. This maneuver is carried out last in a way that allows the separation of the membrane floor without tension, having already separated the membrane from the other sides of the window (Fig 7).

This precise sequence was used in all 21 treated cases. The membrane was elevated using a combination of the mechanical action of the piezosurgical elevators and the high-pressure physiologic solution that is pumped out of the elevator itself. The Valsalva maneuver to diagnose the integrity of the membrane was used in only two cases. It was deemed unnecessary in the other cases after it was quickly ascertained that the membrane had remained intact because the bony window was moving with the respiratory rhythm.

The sinus augmentation procedure was performed using autogenous bone graft mixed with autogenous platelet-rich plasma gel (Figs 8 to 11). The platelet concentration was obtained by a 50-mL venous blood extraction for each sinus procedure, taken 0.5 hour before surgery.^{17–19} After the bone graft was performed and the bioabsorbable membrane (Gore OsseoQuest Regenerative Membrane, 3i/WL Gore) was positioned to cover the bony window and fixed to the bone

with screws, horizontal mattress sutures with Gore-Tex CV5 and separate point stitches with Gore-Tex CV6 (3i/WL Gore) were placed. All cases were evaluated after 6 months with CT examinations with a surgical stent, and afterward No. 45 implants were placed.

Results

The PBWO and PSME in the 21 treated cases produced only one perforation of the membrane, occurring at the site of an underwood septa. This represents a better than 95% success rate for this groundbreaking technique. The one case in which a perforation occurred was resolved during the same surgery by opening another window distal to the underwood septa, where the bone was then grafted. The average length of the osteotomy was 14 mm; its height was 6 mm, and its thickness was 1.4 mm. The smallest window for a sinus augmentation procedure for a single implant was 7 mm in length and 5 mm in height (Figs 12 and 13). In one case, a bony window was removed during the osteotomy phase (Fig 14). The time necessary for the PBWO was approximately 3 minutes, while the PSME required approximately 5 minutes.

Discussion

The perforation of the membrane represents the most frequent complication in standard sinus lift surgery using rotating instruments. To

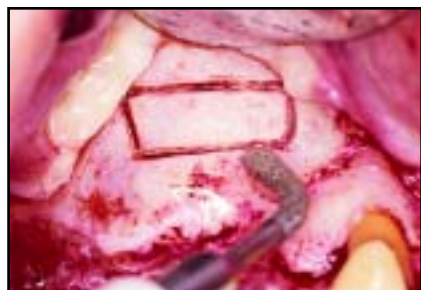

Fig 2 PBWO made by No. 1 piezoelectric scalpel. It is possible to observe the schneiderian membrane, which appears as the frame of the bony window.

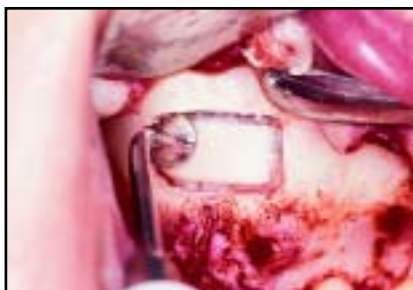

Fig 3 Different clinical case. The initial phase of PSME uses the overturned cone compressor.

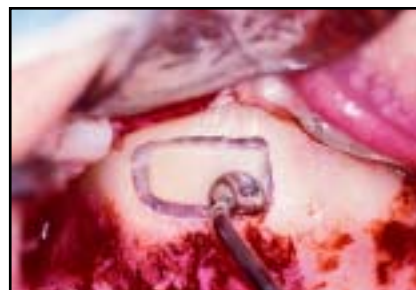

Fig 4 Compressor is inserted into the frame of the window, separating the borders approximately 2 mm.

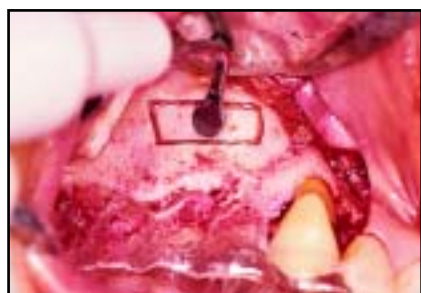


Fig 5 PSME phase two: the elevator in position, ready to work.

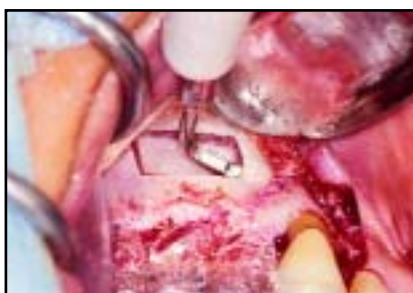

Fig 6 First stage of the membrane elevation begins in the apical position, then in the mesial and distal aspects.

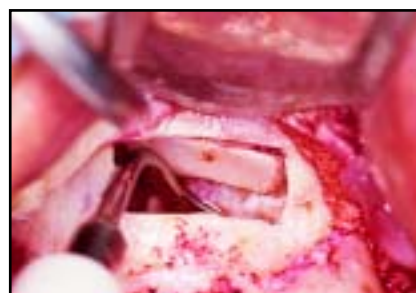


Fig 7 Once the membrane is elevated on three sides, it is possible to separate it from the floor of the sinus, where adhesions are very common, therefore avoiding the risk of perforation.

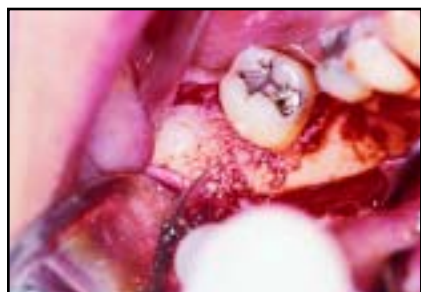

Fig 8 (left) Piezoelectric bone harvesting technique in the mandible.

Fig 9 (right) Volume of bone chips is on average 2.5 cm³ of cortex and medullary bone.

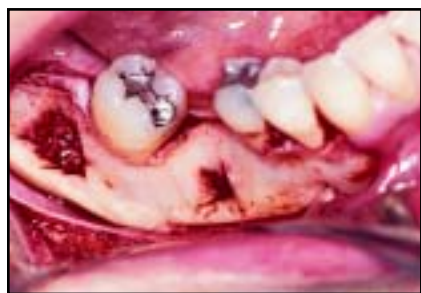

Fig 10 (left) Donor site after the completion of the bone harvesting.

Fig 11 (right) Autologous bone graft mixed with autologous platelet gel fills the sinus cavity.

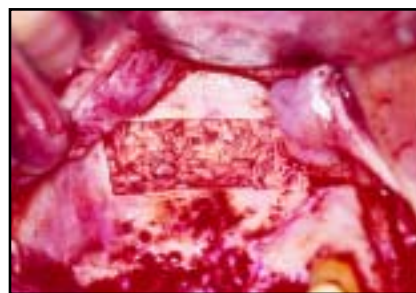

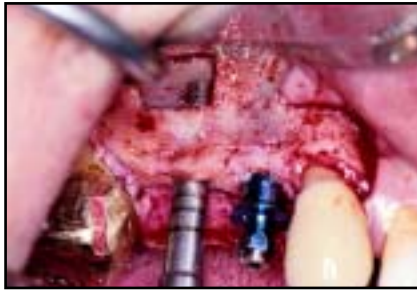


Fig 12 Smallest window thus far performed for a sinus augmentation procedure for a single implant.

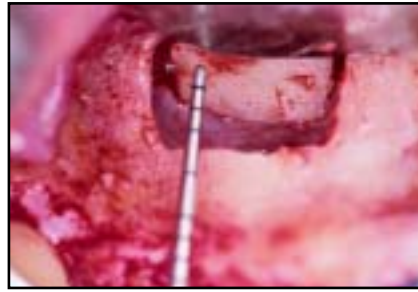

Fig 13 Smallest bony window osteotomy in this study is 5 mm in height and 7 mm in length.

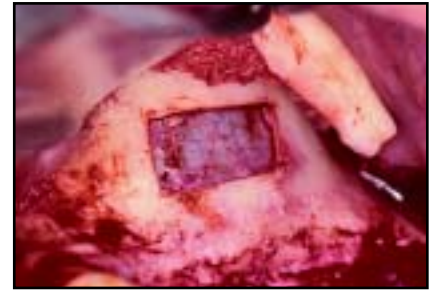


Fig 14 In one case, during the osteotomy the bony window was completely removed.

reduce this eventuality, large-diameter diamond burs are generally used in a way that better allows control of the depth of the cut. Notwithstanding this precaution, perforations occur in 20% to 30% of surgical cases. The occurrence of perforations is relative to the experience of the operator, but even after completion of the learning curve this complication still exists in one in four to five cases.

In 1998, Torrella et al²⁰ described reduced risk of perforating the schneiderian membrane using normal ultrasound instruments for the opening of the bony window. The application of piezoelectric surgery proposed here confirms the validity of the original idea of using simple ultrasound, but it has allowed the development of a repeatable and predictable method by means of a rigorous clinical protocol as demonstrated by the results of the 21 cases. The substantial differences between the use of normal ultrasonic instruments and the piezoelectric method are as follows.

A normal ultrasonic instrument is able to carry out the osteotomy for the opening of the bony window by using only the sharpest tip of the insert; the insufficient power does not allow the use of inserts capable of performing a linear cut. This results in a lower risk of perforation of the membrane in comparison to burs, although perforation remains a frequent occurrence. The insufficient power, however, does not allow the performance of the osteotomy when the bone is highly mineralized or thick. In these cases, the type of tip vibrations and the low power levels of normal ultrasound mean that the instrument does not cut the bone; on the contrary, continued attempts to use these instruments to perform the osteotomy cause an excessive increase in temperature that can lead to bone necrosis.

Piezoelectric surgery uses a specifically engineered surgical instrument characterized by a surgical power that is three times higher than normal ultrasonic instruments. This transfers onto the bone surface

a significantly higher working level than normal ultrasound, and therefore the osteotomy can be performed even when the bone is highly mineralized. The breakthrough device has variable modulations of frequency (25.25 to 30 kHz) that give the inserts a specific vibration that allows the cut to be kept clean of bone splinters. This allows the cut to be made quickly, and for this reason excessive increases in bone temperature are impeded. Furthermore, the physiologic solution can easily cool down the bone.

Ultrasonic instruments have the advantage of not working once they touch soft tissue (and therefore not causing any nerve damage). Nevertheless, piezosurgical instruments allow the elevation of the sinus membrane, the most difficult moment of the sinus lift surgery, especially in the molar-sinus depression. The separation of the endosteum from the flat bone is achieved by the specifically designed inserts working on the internal part of the sinus bone walls and

by the hydropneumatic pressure of the physiologic solution subjected to piezoelectric cavitation.

Conclusion

Piezoelectric surgery is an innovative technique in bone surgery. The new surgical protocol, using piezoelectric instruments to perform the PBWO and PSME, radically reduces the incidence of membrane perforation (no perforations in more than 95% of the 21 study cases treated); the technique therefore allows a much greater success rate than has been previously possible with any other method of advanced implant surgery. These significant advances allow the performance of a surgical technique that greatly reduces complications and operating time and therefore the morbidity of the patient. These advances mean that more dental surgeons will be able to perform advanced implant surgery, making implants an even more attractive alternative for patients with insufficient volume of maxillary crestal bone. Piezoelectric surgery could further simplify sinus surgery in the near future because a new technique in bone harvesting (unpublished data) offers very promising results (Figs 11 to 13).

References

1. Albrektsson T, Zarb GA, Worthington P, Eriksson AR. The long-term efficacy of currently used dental implants. A review and proposed criteria of success. *Int J Oral Maxillofac Implants* 1986;1:11–25.
2. Nevins M, Langer B. The successful application of osseointegrated implants to the posterior jaw: A long-term retrospective study. *Int J Oral Maxillofac Implants* 1993; 8:428–432.
3. Jemt T, Lekholm U. Oral implant treatment in posterior partially edentulous jaws: A 5-year follow-up report. *Int J Oral Maxillofac Implants* 1993;8:635–640.
4. Lekholm U. Osseointegrated implants in the treatment of partially edentulous jaws: A prospective 5-year multicenter study. *Int J Oral Maxillofac Implants* 1994;9: 627–635.
5. Lazzara R, Siddiqui AA, Binon P, et al. Retrospective multicenter analysis of 3i endosseous dental implants placed over a five-year period. *Clin Oral Implants Res* 1996;7:73–83.
6. Cawood JI, Howell RA. A classification of the edentulous jaws. *Int J Oral Maxillofac Surg* 1988;17:232–236.
7. Lozada JL, Emmanuelli S, Boskovic M, Lindsted K. Implants placed in subantral grafted sites. *J Calif Dent Assoc* 1993;21: 21–35.
8. Chanavaz M. Maxillary sinus: Anatomy, physiology, surgery, and bone grafting relating to implantology—Eleven years of clinical experience (1979–1990). *J Oral Implantol* 1990;16:199–209.
9. Academy of Osseointegration Sinus Graft Consensus Conference, Wellesley, Mass, 16–17 1996. *Int J Oral Maxillofac Implants* 1998;13(suppl).
10. Lungren S, Moy P. Augmentation of the maxillary sinus floor with particulate mandible: A histologic and histomorphometric study. *Int J Oral Maxillofac Implants* 1996;11:760–766.
11. Chiappasco M, Ronchi P. Sinus lift and endosseous implants: Preliminary surgical and prosthetic results. *Eur J Prosthodont Restorative Dent* 1994;3:15–21.
12. Fugazzotto PA, Kirsch A, Ackermann K-L, Neuendorff G. Implant/tooth-connected restorations utilizing screw fixed attachments: A survey of 3,096 sites in function for 3 to 14 years. *Int J Oral Maxillofac Implants* 1999;14:819–823.
13. Summers RB. The osteotome technique. Part 3. Less invasive method of elevating the sinus floor. *Compend Contin Educ Dent* 1994;15:698–708.
14. Vlassis JM, Fugazzotto PA. A classification system for sinus membrane perforations during augmentation procedures with options for repair. *J Periodontol* 1999;70: 692–699.
15. Vercellotti T. Piezoelectric surgery in implantology: A case report—A new piezoelectric ridge expansion technique. *Int J Periodontics Restorative Dent* 2000; 20:358–365.
16. Vercellotti T, Russo C, Gianotti S. A new piezoelectric ridge expansion technique in the lower arch—A case report [online article]. *World Dent* 2000;1(2).
17. Marx RE, Carlson ER, Eichstaed RM, Schimmele SR, Strauss JE, Georgeff KR. Platelet rich plasma growth factor enhancement for bone graft. *Oral Surg Oral Med Oral Pathol Oral Radiol Endod* 1998;85:638–646.
18. Sacchi MC, Bellanda M, Vercellotti T. Il concentrato piastrinico in chirurgia orale e implantare. *Dent Mod* 2000;1:69–78.
19. Marx RE. Platelet-rich plasma: A source of multiple autologous growth factors for bone grafts. In: Lynch SE, Genco RJ, Marx RE (eds). *Tissue Engineering: Applications in Maxillofacial Surgery and Periodontics*. Chicago: Quintessence, 1999:179–198.
20. Torrella F, Pitarch J, Cabanes G, Anitua E. Ultrasonic osteotomy for the surgical approach of the maxillary sinus: A technical note. *Int J Oral Maxillofac Implants* 1998;13:697–700.