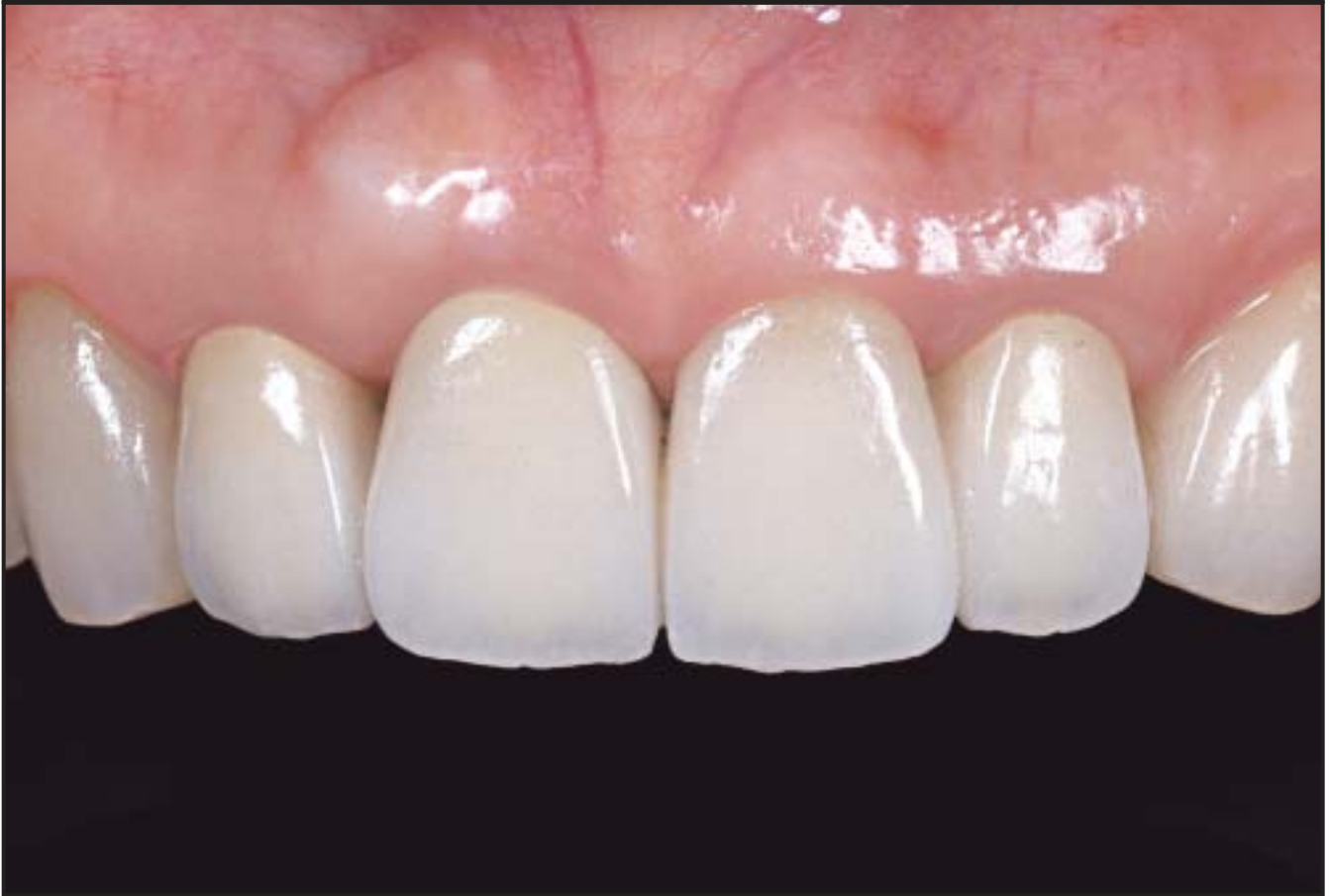
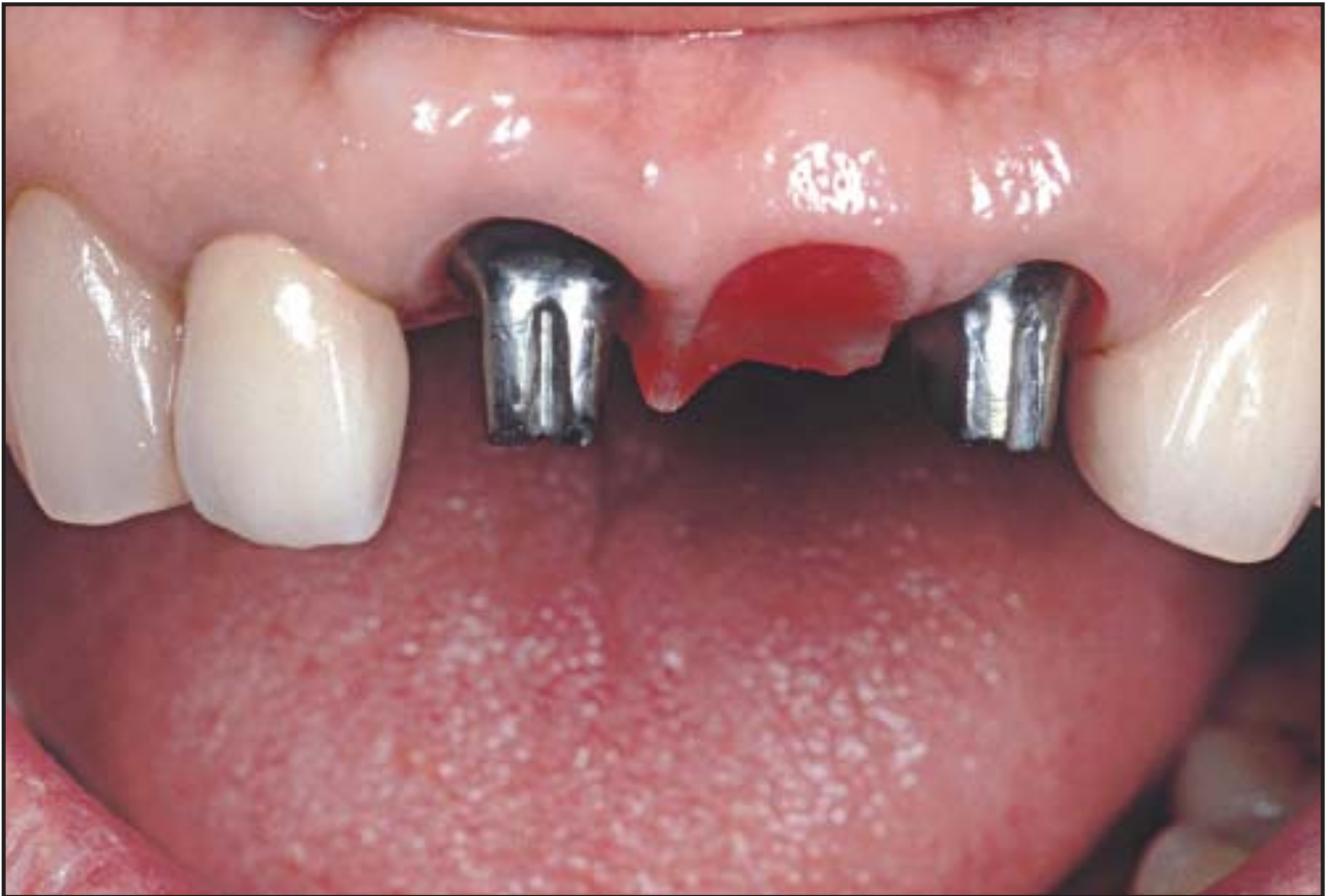
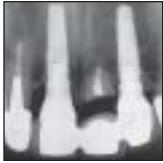

Advantages of the Root Submergence Technique for Pontic Site Development in Esthetic Implant Therapy



Maurice Salama, DMD*
 Tomohiro Ishikawa, DDS**
 Henry Salama, DMD***
 Akiyoshi Funato, DDS****
 David Garber, DMD*

A single-tooth implant in the esthetic region has good potential for success, but it is still challenging to restore multiple-tooth defects with implant-supported prostheses that resemble the natural dentition. This article suggests a strategy to provide a more predictable protocol for esthetic implant treatment for multiple-tooth defects using the root submergence technique (RST). By maintaining the natural tooth root with the RST, a much greater amount of surrounding tissue may be preserved than with the commonly used socket preservation technique, which almost always leads to crestal bone resorption and thus reduction of the height of the interdental papillae and width of the edentulous ridge. RST instead maintains the natural attachment apparatus of the tooth in the pontic site, which in turn allows for complete preservation of the alveolar bone frame and assists in the creation of an esthetic result in adjacent multiple-tooth-replacement cases. In situations with periodontal bone loss, orthodontic extrusion is required to create the underlying bone support for the papilla that is necessary to guarantee predictability. (Int J Periodontics Restorative Dent 2007;27:521–527.)

*Clinical Assistant Professor of Periodontics, University of Pennsylvania, Philadelphia, Pennsylvania; Medical College of Georgia, Augusta, Georgia; Private Practice, Atlanta, Georgia.

**Private Practice, Hamamatsu, Shizuoka, Japan.

***Clinical Assistant Professor of Periodontics, University of Pennsylvania, Philadelphia, Pennsylvania; Private Practice, Atlanta, Georgia.

****Private Practice, Kanazawa, Ishikawa, Japan.

Correspondence to: Dr Maurice Salama, 600 Galleria Parkway, Suite 800, Atlanta, Georgia 30339; fax: +404-261-4946.

This article suggests a strategy to provide a more predictable protocol for esthetic implant treatment for multiple-tooth defects using the root submergence technique (RST). The RST maintains the natural attachment apparatus of the tooth in the pontic site, which in turn allows for complete preservation of the alveolar bone frame and assists in the creation of an esthetic result in adjacent multiple-tooth-replacement cases.

Effectiveness of a pontic

To obtain an esthetic soft tissue frame, the underlying alveolar bone frame must be present to support it. Many procedures, including horizontal and vertical augmentation of the lost osseous tissue, have been documented, with varying levels of predictability.^{1–4} However, once an implant is placed into the function, the biologic width is reestablished around the implant. This triggers peri-implant bone remodeling and resorption.⁵ Tarnow et al⁶ have suggested that, if the distance between adjacent implants is less than 3 mm, the height of the alveolar bone

Table 1 Salama et al¹¹ classification of predicted height of interdental papillae

Class	Restorative environment	Proximity limitations (mm)	Vertical soft tissue limitations (mm)
1	Tooth-tooth	1.0	5.0
2	Tooth-pontic	N/A	6.5
3	Pontic-pontic	N/A	6.0
4	Tooth-implant	1.5	4.5
5	Implant-pontic	N/A	5.5
6	Implant-implant	3.0	3.5

decreases, the creation of an ideal interdental papilla becomes difficult, and gingival recession occurs in the area before it stabilizes.

Currently, several techniques, including the scalloped implant⁷ and platform switching,⁸ have been developed in an attempt to control alveolar bone resorption and preserve crestal bone height around adjacent implants. Recently, a procedure that controls the influence of remodeling by augmenting the alveolar ridge width to obtain more than 2 mm on the labial aspect of an implant has been reported, with positive results.⁹

However, clinical hurdles remain to be overcome. Berglundh et al¹⁰ noted that the blood supply to the peri-implant soft tissue is less than that to a natural tooth, and although bone resorption between implants or circumferentially around implants is controlled to some degree, the eventual height of soft tissue around adjacent implants is still lower than that around an adjacent natural tooth or pontic.^{11,12} It appears, from the body of current evidence, that the treatment of multi-

ple teeth is more effective when placement of adjacent implants is avoided; instead, segregation of implants by insertion of a pontic is recommended (Table 1).

Predictability and procedure of the root submergence technique

In the second half of the 1960s, clinicians documented a procedure that involved resecting the crown of a tooth, covering it with a buccal or buccolingual flap, and submerging the root in animals and humans. This procedure, known as the RST,¹³ was originally created to prevent alveolar bone resorption after extraction of teeth. In most cases, dental pulps were vitally preserved or root canal treatments were performed before or during the procedure. The purpose of this procedure was to prevent epithelial down-growth in periodontal regeneration procedures or to maintain the alveolar ridge height and frame. Howell¹³ claimed that the alveolar bone under

complete dentures did not resorb following more than 10 years' observation of submerged endodontically treated roots.

O'Neal et al¹⁴ performed a 30- to 120-day histologic examination of 16 endodontically treated submerged roots in dogs that were cut at 2 mm below the bone edge. They reported that 62.5% of root specimens had more than half of their cut surfaces covered with bone and identified complete bone coverage on the cut surfaces of the 60-day specimens. Their research showed that osteocementum and a connective tissue layer had formed between the cut surface and the newly formed bone.

In 1975, Guyer¹⁵ submerged vital roots for the first time in a human and reported that the two roots displayed radiographically normal conditions and the alveolar ridge frames were maintained clinically for 27 months. In 1976, Plata et al¹⁶ performed a 12-week histologic evaluation of 12 vital submerged roots that were cut at 2 mm below the bone edge. They reported that eight of the roots had complete

bone coverage on the cut surfaces, and all pulps were vitally retained.

Bowers et al¹⁷ submerged vital teeth with infrabony defects in nine patients and created notches at regions on the root that had been covered with dental calculus. They performed vital RST on 30 regions with bone graft (demineralized freeze-dried bone allograft) and on 13 regions without bone graft. After 6 months, all 43 regions were evaluated histologically. The volume and frequency of formation of bone, cementum, and new attachment increased with the use of bone graft, and there was potential for the formation of a new attachment apparatus on the cut surface of the dentin. This study showed that epithelial exclusion with bone grafts and root submergence could treat infrabony defects with a higher level of predictability. No root resorption, ankylosis, or pulp death was observed.

Documented complications with the RST involved gingival tissue perforation and cyst formation, but necrotic and infected dental pulps have seldom been reported. This suggests that, to prevent a perforation, roots should be excised so that they are positioned slightly lower than the bone edge and then beveled to avoid exposed, sharp edges.

Von Wöern and Winter¹⁸ published a 4-year follow-up study of 20 cases of crown-resected, endodontically treated roots. They reported that gingival tissue perforation occurred in 11 cases, which they designated as failures. If roots were submerged and dentures were placed, the alveolar ridge was often not preserved. There are no similar reports of gingival per-

foration or exposure associated with pontic sites where occlusal forces are not directly acting on the gingiva. Harper¹⁹ submerged an endodontically treated root in the anterior maxilla and successfully followed up, over a 6-year period, a combined "submerged root/pontic" site.

Root submergence in the esthetic pontic site

The attachment apparatus of natural teeth maintains and augments the shape of alveolar bone, as well as the gingival and alveolar mucosa. Salama et al²⁰ showed that orthodontic extrusion of teeth with advanced periodontal disease can help eliminate deep infrabony defects and may allow for more optimal implant placement with a higher level of esthetic predictability. The authors later suggested that improvements in the height and position of the interproximal height of bone work effectively to achieve normal heights of the interdental papillae.¹¹ Schropp et al²¹ reported that tooth extraction triggers resorption of the surrounding tissues, and the width of the alveolar ridge decreases by up to 50% a year. Nevins et al²² recently suggested that socket preservation procedures can control alveolar ridge resorption to some degree, but only rarely can such procedures completely preserve the alveolar ridge frame.

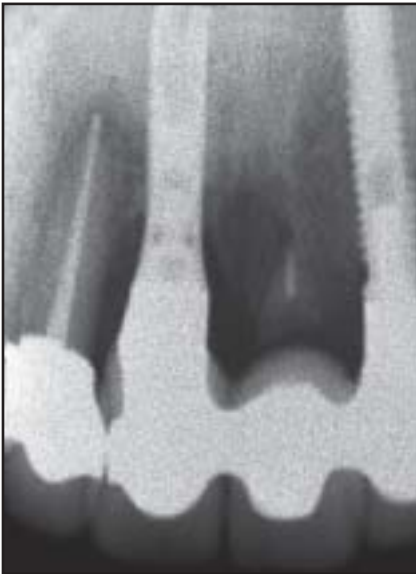
Immediate implant placement does not stop the process of socket and ridge remodeling, and on its own, it proves problematic in controlling alveolar bone resorption.²³ Clinicians should therefore always consider the

appropriate timing of procedures involving extraction, implant placement, and augmentation of the peri-implant tissue to prevent added clinical difficulty.²⁴

Esthetic implant treatment is more difficult for multiple-tooth defect sites than for single-tooth defects, because an ideal soft tissue frame with intact interdental papillae is difficult to create without an adjacent intact natural tooth attachment apparatus.

In patient 1 (Fig 1), a mutilated dentition features three previously endodontically treated hopeless teeth in the maxillary anterior region (both central incisors and the left lateral incisor). As part of the treatment, these teeth were extracted and implants were placed in the areas of the right central incisor and left lateral incisor, while the left central incisor was submerged at the crest of the bone. A soft tissue graft was added over the top. This form of treatment (Figs 1g to 1i) showcases the RST, which allowed for the alveolar crestal bone to be maintained around the retained residual root and used the implants adjacent to the natural teeth to support an ideal soft tissue profile. Radiographic review at 27 months postoperative (Fig 1i) shows that the root was retained with intact crestal levels of bone to support the ideal contours of the pontic site in the definitive restoration. In patient 2 (Fig 2), a severely compromised dentition was treated using orthodontic site development²⁰ with retraction and extrusion of the maxillary anterior teeth, followed by extraction and root submergence of the maxillary right central incisor to maintain the crestal bone. Again, this technique created an ideal

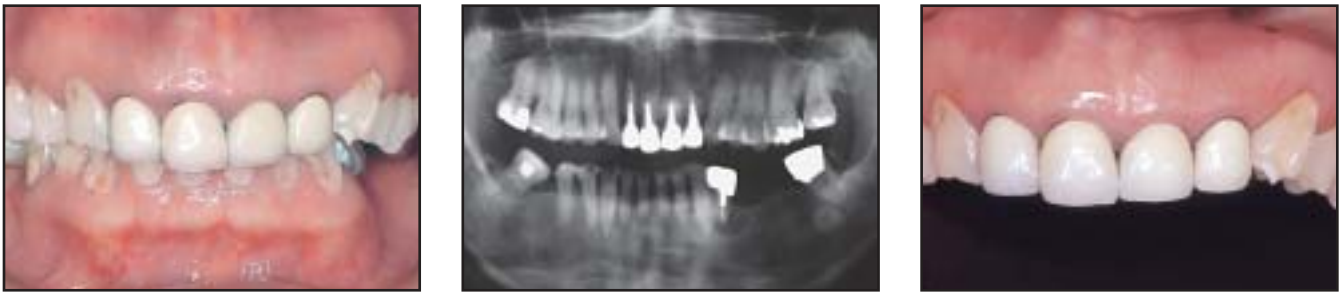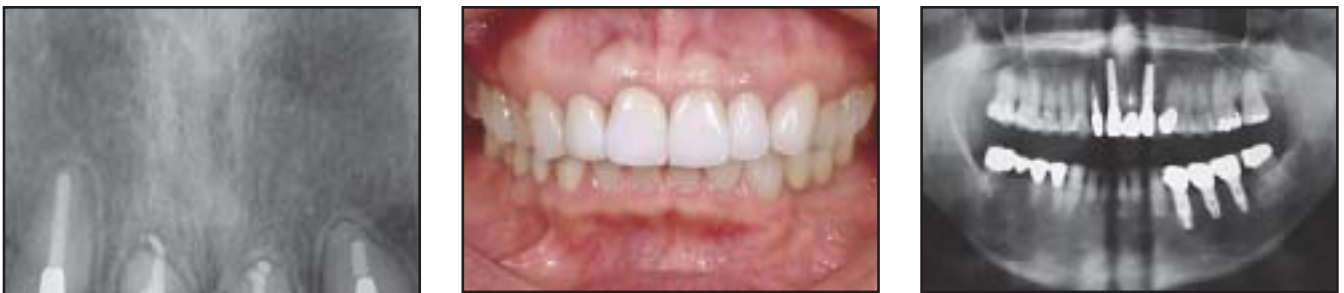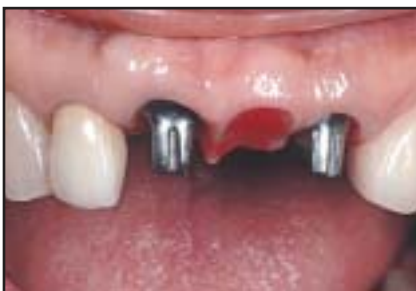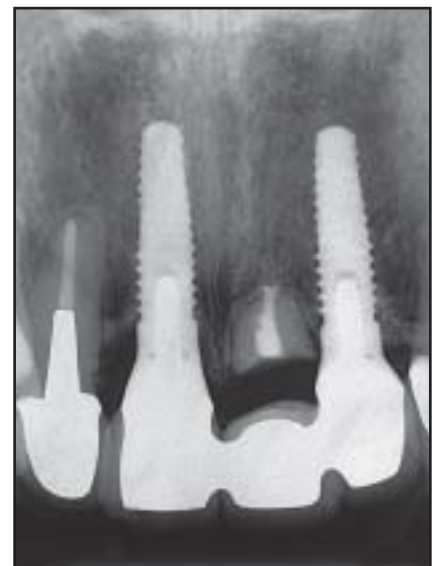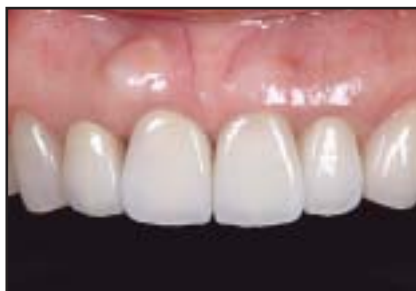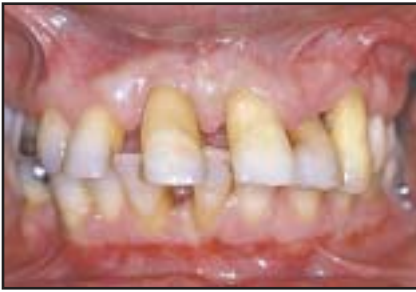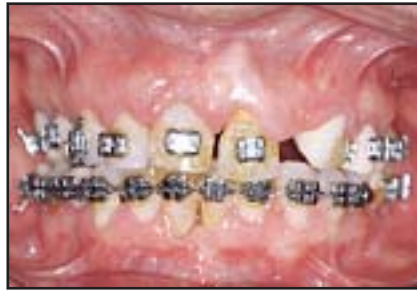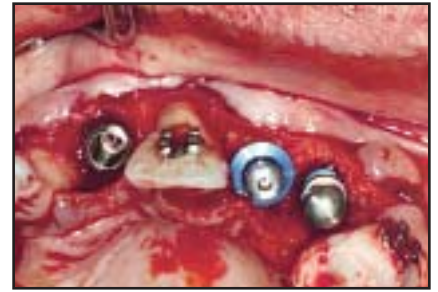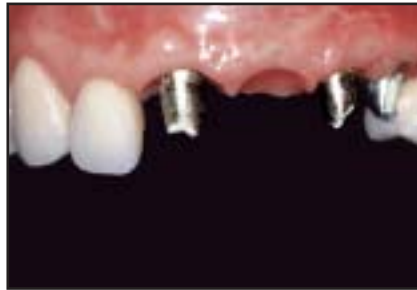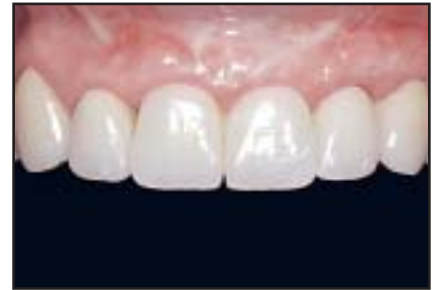Fig 1 Patient 1.**Figs 1a to 1c** Clinical and radiographic appearance of a 55-year-old woman who presented with esthetic and masticatory disturbances.**Fig 1d** (left) Periapical radiograph of the anterior teeth after orthodontic therapy. Both central incisors and the left lateral incisor were planned to be replaced by an implant-supported restoration.**Fig 1e** (above center) Anterior view of the result. Esthetics and function are maintained. An interdisciplinary approach was needed.**Fig 1f** (above right) Posttreatment orthopantomograph of the patient. Positions of the teeth and implants are optimal.**Fig 1g** (above left) The pontic site shows excellent shape owing to the submerged root.**Fig 1h** (above center) The definitive restoration looks natural. The submerged root of the right maxillary central incisor maintains the surrounding alveolar bone and soft tissues of the pontic in the most coronal position. A normal pontic is not typically able to reproduce these ideal tissue frames and papilla heights because of a lack of needed underlying bone support.**Fig 1i** (right) Posttreatment periapical radiograph obtained 27 months after root submergence. The submerged root maintains an ideal mesiodistal alveolar bone level.

Fig 2 Patient 2.**Fig 2a** The patient presented with severe periodontal attachment loss and malocclusion.**Fig 2b** Clinical view following orthodontic extrusion of maxillary incisors to improve vertical hard and soft tissue support prior to implant placement. Correction of the underlying malocclusion was also achieved.**Fig 2c** Implants were placed at the time of extraction in the areas of the right central incisor, the left lateral incisor, and the left canine. The left central incisor was kept to serve as an abutment during provisionalization and for the RST.**Fig 2d (left)** One-year postoperative radiograph of the area of root submergence (left central incisor). Note the preserved interproximal heights of bone around the submerged root.**Fig 2e (above center)** Final soft tissue framework and implant abutments in the adjacent areas prior to cementation.**Fig 2f (above right)** Definitive ceramic restoration at 1 year. Note the esthetic harmony and maintenance of the health and esthetics of the pontic in the left central incisor area.

form and soft tissue profile for the definitive implant-supported restoration (Fig 2f). In patient 3 (Fig 3), the implants were separated by multiple vital submerged roots, followed by soft tissue grafting over the top of the submerged roots to maintain the crestal bone for ideal soft tissue contouring of the definitive implant-supported restoration. All three patients display the successful use of the RST to maintain the vertical scaffold of the alveolar bone around the submerged root for ideal soft tissue support and esthetics.

As described, the use of pontics rather than adjacent placement of implants can work effectively. On the other hand, in their six classifications (see Table 1), Salama et al²⁵ suggested that the interdental papillae between an implant and a natural tooth has the second highest ranking after two adjacent natural teeth. From a prosthetic viewpoint, this mixed environment of natural teeth and implants is difficult to control, and establishment of a protective occlusal scheme is challenging. Multiple implants alone occasion-

ally have an advantage over a combination of natural teeth and implants in cases of multiple missing adjacent teeth. In such cases, the preoperative plan sometimes determines that a remaining tooth should be replaced by a pontic. Taking into account the predictability of the RST described here and its ability to maintain and preserve the vertical height of alveolar bone for esthetics, the common practice of extracting the remaining tooth should not be considered as the only option. The RST should be considered from

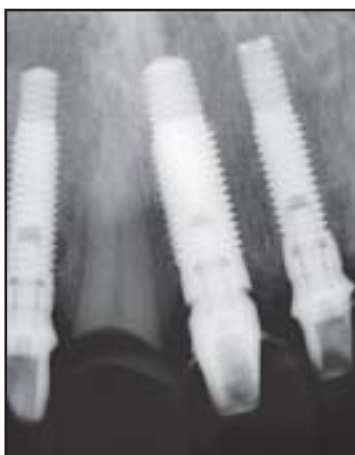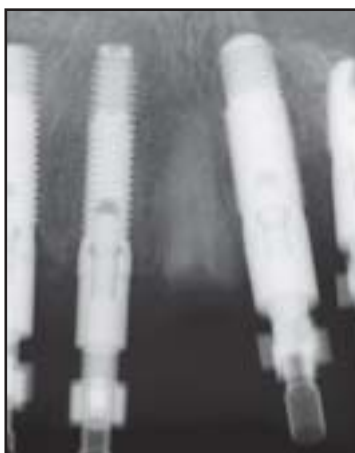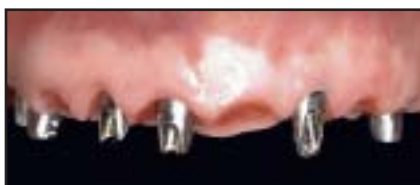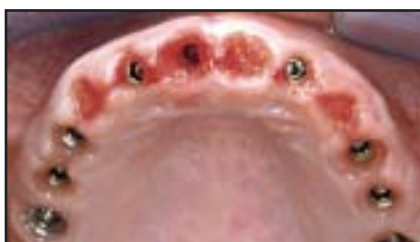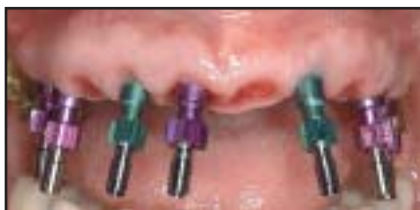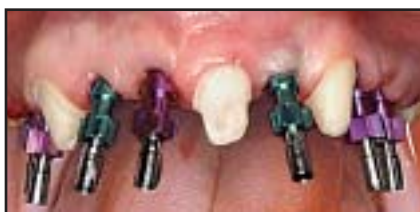Fig 3 Patient 3.

Fig 3a (far top) Multiple implants in the maxillary arch. The right canine, left central incisor, and left first premolar, which were vital but hopeless, were maintained only for the provisional phase.

Fig 3b (far bottom) The roots of the three remaining teeth were submerged using the RST, and additional soft tissue was grafted over the top.

Fig 3c (left) Radiograph of submerged vital root of the right canine at the time of impression taking.

Fig 3d (far top) Occlusal view of the maxilla at abutment placement. Notice the ideal ridge form maintained by the RST.

Fig 3e (far bottom) Following abutment placement and provisionalization, the esthetics of the soft tissue around the three submerged root pontic sites can be observed.

Fig 3f (left) Radiograph of the submerged root of the left central incisor and adjacent implant abutments following final cementation. Notice the maintained crestal bone and anterior interproximal scallop of the submerged root, which preserves the soft tissue esthetics.

the beginning of the treatment plan as a useful strategy in esthetic anterior tooth replacement.

In some complex defects, the use of the RST following orthodontic extrusion of the remaining root has been extremely successful in establishing ideal pontic form. In these situations, use of the implant-supported provisional prosthesis as an orthodontic anchor may help reproduce interdental papillae in the best possible vertical positions and achieve the volume

of alveolar bone necessary on the labial side of the pontic space. The RST allows for an improved esthetic result with long-term predictability when restoring multiple adjacent teeth in the esthetic zone.

Conclusion

Although implant technology is constantly improving, it is safe to assume that implants will never surpass the

natural tooth's ability to preserve the surrounding bone and soft tissue height. The RST not only eliminates the risk of caries and periodontitis, but more important, the retention of a natural tooth root allows for maximum preservation of the surrounding alveolar bone and soft tissues.

The RST was introduced to preserve the alveolar ridge; later it was used to prevent downgrowth of epithelium during the regeneration of periodontal tissues. Today, the con-

cepts and techniques of osseointegration, periodontal plastic surgery, tissue regeneration, and esthetic restoration have dramatically advanced our field. The authors further postulate that the RST should be recognized anew as a very effective technique for maximum tissue preservation and esthetics for pontic sites in the esthetic zone.

Acknowledgments

The authors would like to thank Dr Myron Nevins and Dr Yoshihiro Ono for their encouragement and support.

References

- Buser D, Dula K, Belser U, et al. Localized augmentation using guided bone regeneration. 1. Surgical procedure in the maxilla. *Int J Periodontics Restorative Dent* 1993;13:29–45.
- Simion M, Badoni M, Rossi P, Zaffe D. A comparative study of the effectiveness of e-PTFE membranes with and without early exposure during the healing period. *Int J Periodontics Restorative Dent* 1994;14:167–180.
- Gher M, Quintero G, Assad D, et al. Bone grafting and guided bone regeneration for immediate dental implants in humans. *J Periodontol* 1994;65:881–891.
- Becker B, Becker W. Guided tissue regeneration for implants placed into extraction sockets and for implant dehiscence: Surgical techniques and case reports. *Int J Periodontics Restorative Dent* 1990;10:377–391.
- Cochran DL, Hermann JS, Schenk RK, Higginbottom FL, Buser D. Biologic width around titanium implants. A histometric analysis of the implant-to-gingival junction around unloaded and loaded nonsubmerged implants in the canine mandible. *J Periodontol* 1997;68:186–197.
- Tarnow DP, Cho SC, Wallace SS. The effect of inter-implant distance on the height of inter-implant bone crest. *J Periodontol* 2000;71:546–549.
- Wohrle PS. NobelPerfect esthetic scalloped implant: Rationale for a new design. *Clin Implant Dent Relat Res* 2003;5(suppl 1):64–73.
- Lazzara RJ, Porter SS. Platform switching: A new concept in implant dentistry for controlling postrestorative crestal bone levels. *Int J Periodontics Restorative Dent* 2006;26:9–17.
- Grunder U, Gracis S, Capelli M. Influence of the 3-D bone-to-implant relationship on esthetics. *Int J Periodontics Restorative Dent* 2005;25:113–119.
- Berglundh T, Lindhe J, Jonsson K, Ericsson I. The topography of the vascular systems in the periodontal and peri-implant tissues in the dog. *J Clin Periodontol* 1994;21:189–193.
- Salama H, Salama MA, Garber D, Adar P. The inter-proximal height of bone: A guidepost to predictable aesthetic strategies and soft tissue contours in anterior tooth replacement. *Pract Periodontics Aesthet Dent* 1998;10:1131–1141.
- Tarnow D, Elian N, Fletcher P, et al. Vertical distance from the crest of bone to the heights of the interproximal papilla between adjacent implants. *J Periodontol* 2003;74:1785–1788.
- Howell F. Retention of alveolar bone by endodontic root treatment. *Seminario Annual del Grupo de Estudios Dentales U.S.C de Mexico* 23, May 1970.
- O'Neal R, Gound T, Levin MP, del Rio BCE. Submergence of roots for alveolar bone preservation. I. Endodontically treated roots. *Oral Surg Oral Med Oral Pathol* 1978;45:803–810.
- Guyser SE. Selectively retained vital roots for partial support of overdentures: A patient report. *J Prosthet Dent* 1975;33:258–263.
- Plata RL, Kelln EE, Linda L. Intentional retention of vital submerged roots in dogs. *Oral Surg* 1976;42:100–108.
- Bowers GM, Chadroff B, Carnevale R, et al. Histologic evaluation of new attachment apparatus formation in humans. Part II. *J Periodontol* 1989;60:675–682.
- Von Wowern N, Winther S. Submergence of roots for alveolar ridge preservation. A failure (4-year follow-up study). *Int J Oral Surg* 1981;10:247–250.
- Harper KA. Submerging an endodontically treated root to preserve the alveolar ridge under a bridge—A case report. *Dent Update* 2002;29:200–203.
- Salama H, Salama MA. The role of orthodontic extrusive remodeling in the enhancement of hard and soft tissue prior to implant placement: A systematic approach to the management of extraction site defects. *Int J Periodontics Restorative Dent* 1993;13:313–334.
- Schropp L, Wenzel A, Kostopoulos L, Karring T. Bone healing and soft tissue contour changes following single tooth extraction: A clinical and radiographic 12-month prospective study. *Int J Periodontics Restorative Dent* 2003;23:313–323.
- Nevins M, Camelo M, De Paoli S, et al. A study of the fate of the buccal wall of extraction sockets of teeth with prominent roots. *Int J Periodontics Restorative Dent* 2006;26:19–29.
- Araujo MG, Sukekava F, Wennstrom JL, Lindhe J. Ridge alterations following implant placement in fresh extraction sockets: An experimental study in the dog. *J Clin Periodontol* 2005;32:645–652.
- Funato A, Salama M, Ishikawa T, Garber D, Salama H. Timing, positioning, and sequential staging in esthetic implant therapy: A four-dimensional perspective. *Int J Periodontics Restorative Dent* 2007;27:313–323.
- Salama M, Salama H, Garber D. Guidelines for aesthetic restorative options and implant site enhancement: The utilization of orthodontic extrusion. *Pract Periodontics Aesthet Dent* 2002;14:125–130.