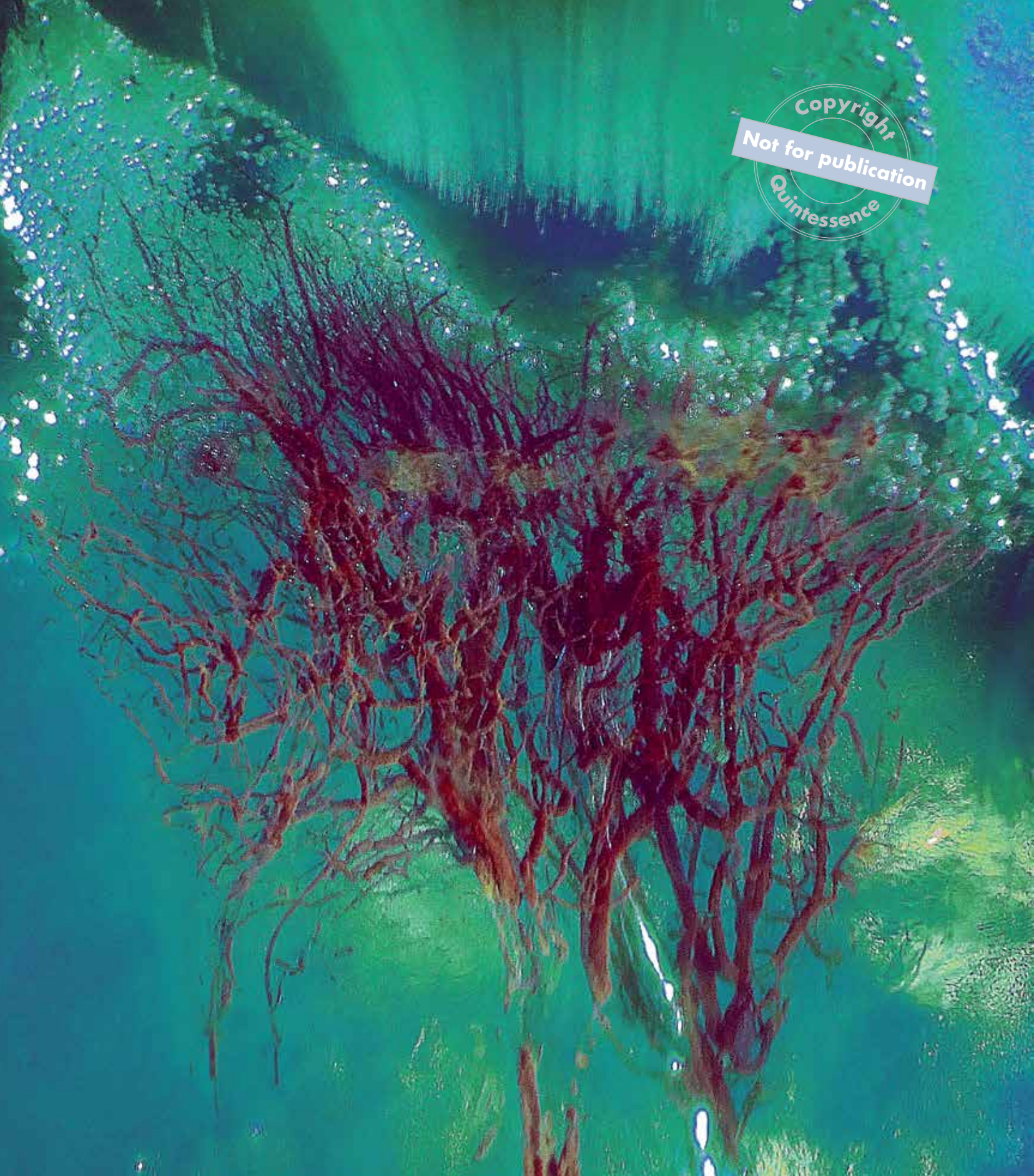
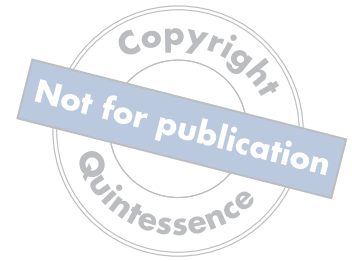


An Atlas of Human Dental Vascularity and Innervation



Copyright  
Not for publication  
Quintessence



*An Atlas of*  
**Dental Vascularity  
& Innervation**

Craig Barrington, DDS

Private Practice  
Waxahachie, Texas

 **QUINTESSENCE PUBLISHING**

Berlin | Chicago | Tokyo  
Barcelona | London | Milan | Mexico City | Moscow | Paris | Prague | Seoul | Warsaw  
*Beijing | Istanbul | Sao Paulo | Zagreb*



Library of Congress Cataloging-in-Publication Data

Names: Barrington, Craig, author.

Title: An atlas of dental vascularity & innervation / Craig Barrington.

Other titles: Atlas of dental vascularity and innervation

Description: Batavia, IL : Quintessence Publishing, [2021] | Includes bibliographical references. |

Summary: "This book documents the internal anatomy of teeth, with a special focus on the innervation and vascular structure and distribution within the dentin chamber. Instead of the common use of sectioning, the author uses a complex diaphanization method to make extracted teeth transparent before photographing the intact internal dental anatomy. Therefore, the images throughout the book display structures that have rarely been seen so clearly and in three dimensions, including clear photographs of the pulp chamber, apical anatomy, and tooth channels. The body of work represented in this book pushes our understanding of internal dental anatomy"— Provided by publisher.

Identifiers: LCCN 2021030983 | ISBN 9781647241001 (hardcover)

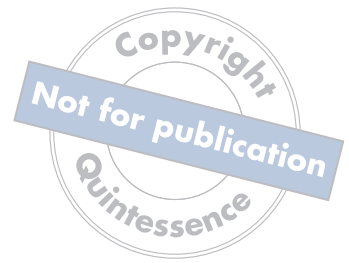Subjects: MESH: Tooth--anatomy & histology | Atlas

Classification: LCC QP88.6 | NLM WU 17 | DDC 612.3/11--dc23

LC record available at <https://lcn.loc.gov/2021030983>

A CIP record for this book is available from the British Library.

ISBN: 9781647241001



© 2022 Quintessence Publishing Co, Inc

Quintessence Publishing Co, Inc

411 N Raddant Road

Batavia, IL 60510

[www.quintpub.com](http://www.quintpub.com)

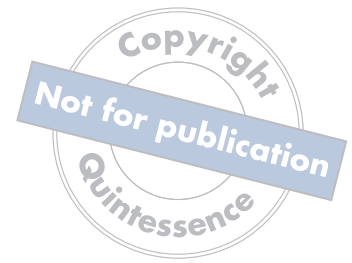5 4 3 2 1

All rights reserved. This book or any part thereof may not be reproduced, stored in a retrieval system, or transmitted in any form or by any means, electronic, mechanical, photocopying, or otherwise, without prior written permission of the publisher.

Editor: Bryn Grisham

Design & production: Sue Zubek

Printed in Croatia

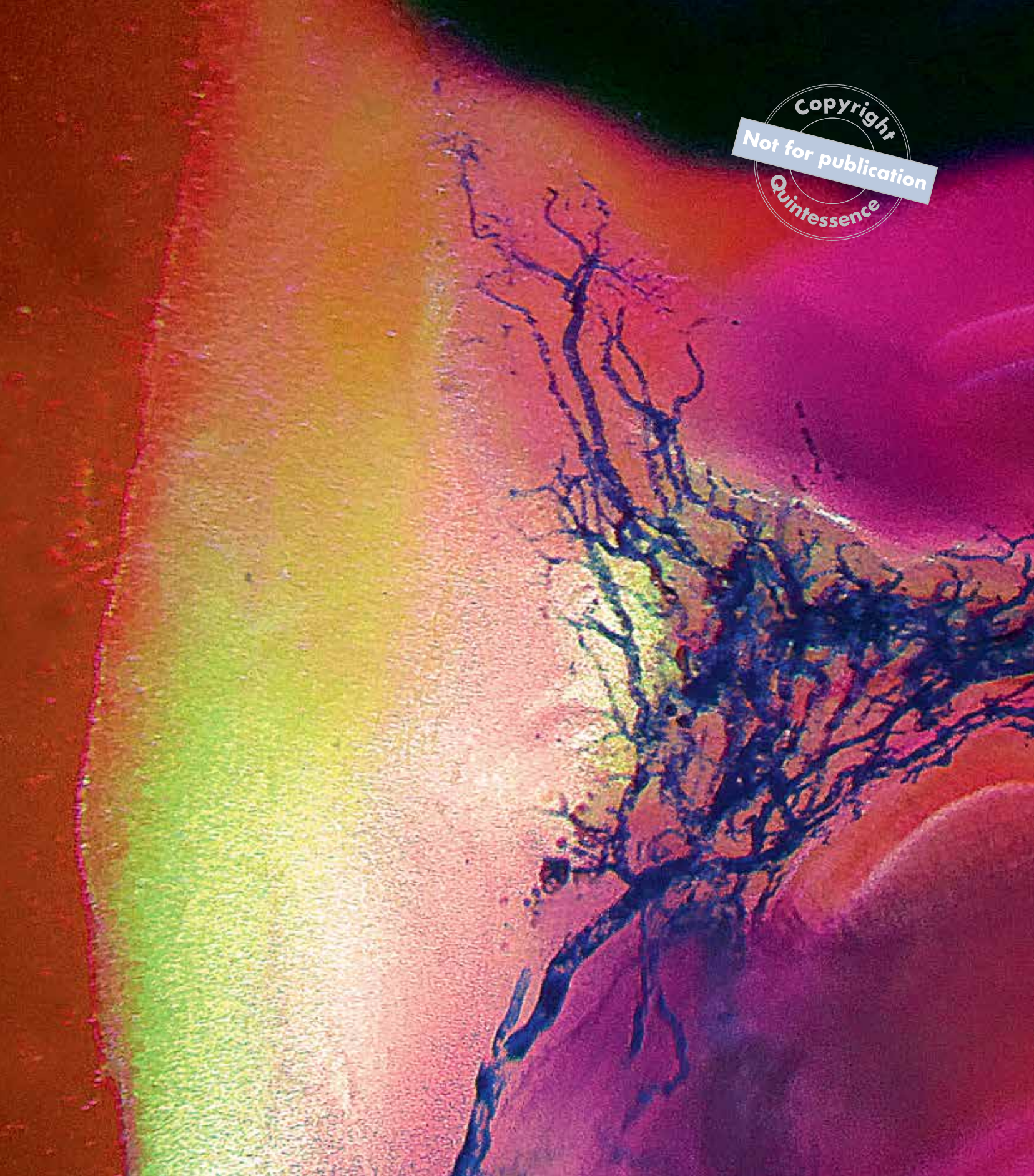

*For my parents who have never stopped supporting me and who have always had faith in me.*

*I would also like to thank my brothers, my wife, and my kids for their continued support and feedback.*

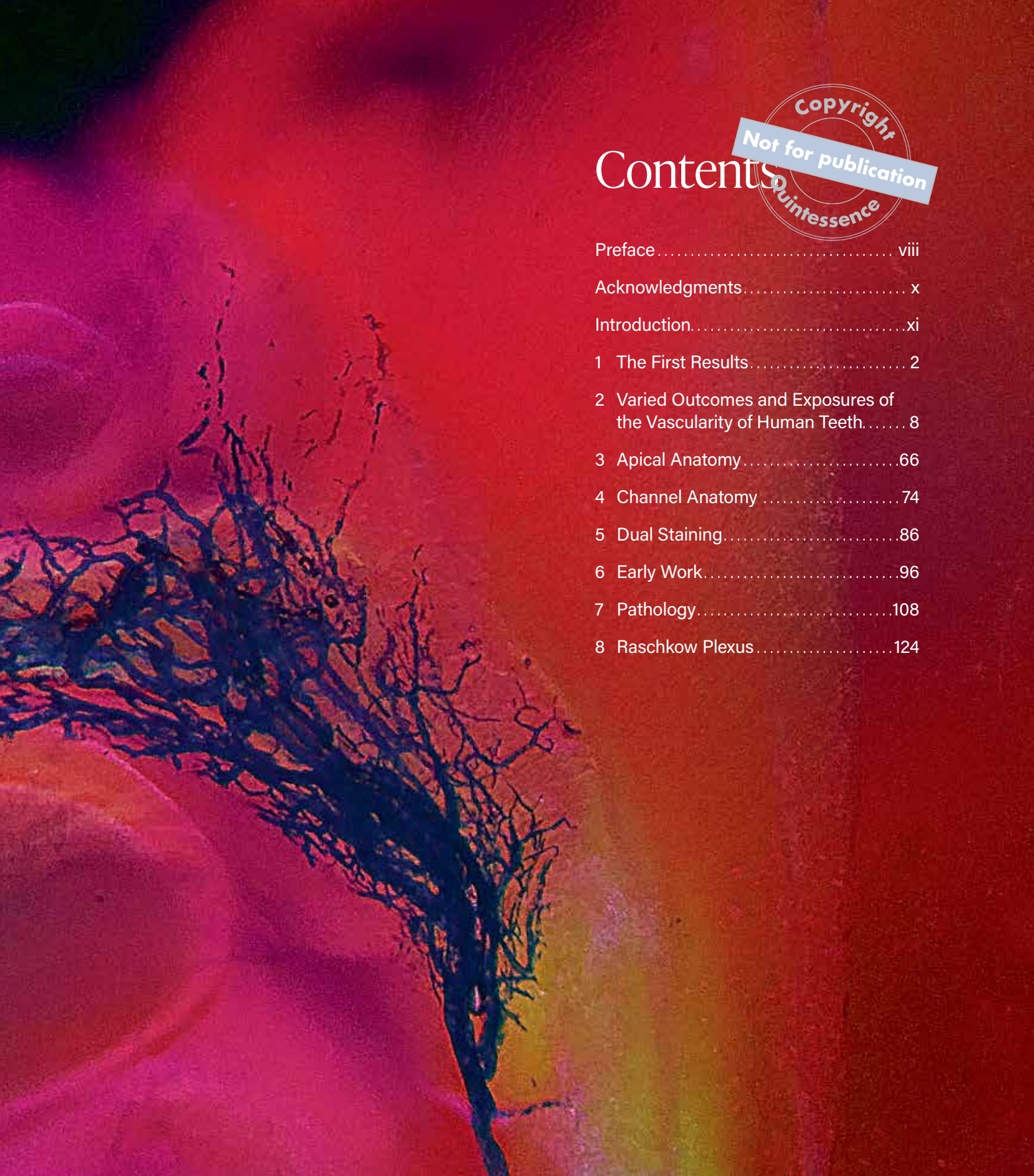*There is a God. There has to be. There is no other explanation, as far as I can tell.*





copyright  
Not for publication  
Quintessence

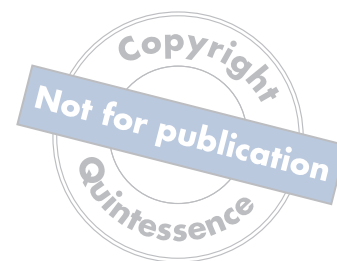



# Contents

Preface.....	viii
Acknowledgments.....	x
Introduction.....	xi
1 The First Results.....	2
2 Varied Outcomes and Exposures of the Vascularity of Human Teeth.....	8
3 Apical Anatomy.....	66
4 Channel Anatomy.....	74
5 Dual Staining.....	86
6 Early Work.....	96
7 Pathology.....	108
8 Raschkow Plexus.....	124

# Preface



“Respect for life requires that science and technology should always be at the service of man and his integral development. Society as a whole must respect, defend, and promote the dignity of every human person, at every moment and in every condition of that person’s life.”

—Pope John Paul II, *Evangelium Vitae*

Over the years, when I have shown some of these images to people, the reactions are universally profound. Most of the time, I get a comment to this effect: “These are works of art, you should sell them!” It has been my thought that to sell or profit from these images would be inappropriate or even unethical. Even if these photographs are considered works of art, they are still images of human extracted teeth. It might be an exaggeration but I see it as akin to some form of human trafficking of human body parts.

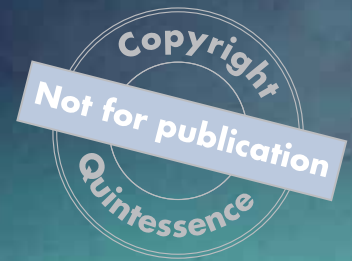Secondarily, the person that these extracted teeth came from should be given the opportunity share in any profits I would receive from selling pictures. However, there is only one case in this book in which I know the patient to whom the tooth actually belongs. Otherwise, I have no clue to whom the extracted teeth belong, and there would be virtually no way to trace, track, or attach the results to the human donor.

I have looked into the ethics regarding what I have accomplished, in terms of revealing the internal anatomy of extracted human teeth. I have made phone calls to the sources listed by the American Dental Association, spoken with leaders at dental schools, read books, and consulted with many people. Repeatedly, the answers I get are “keep going” or “you’re fine, they’re just teeth.” With that, I have continued to work toward better and better results, knowing one day that this topic would need to be approached.

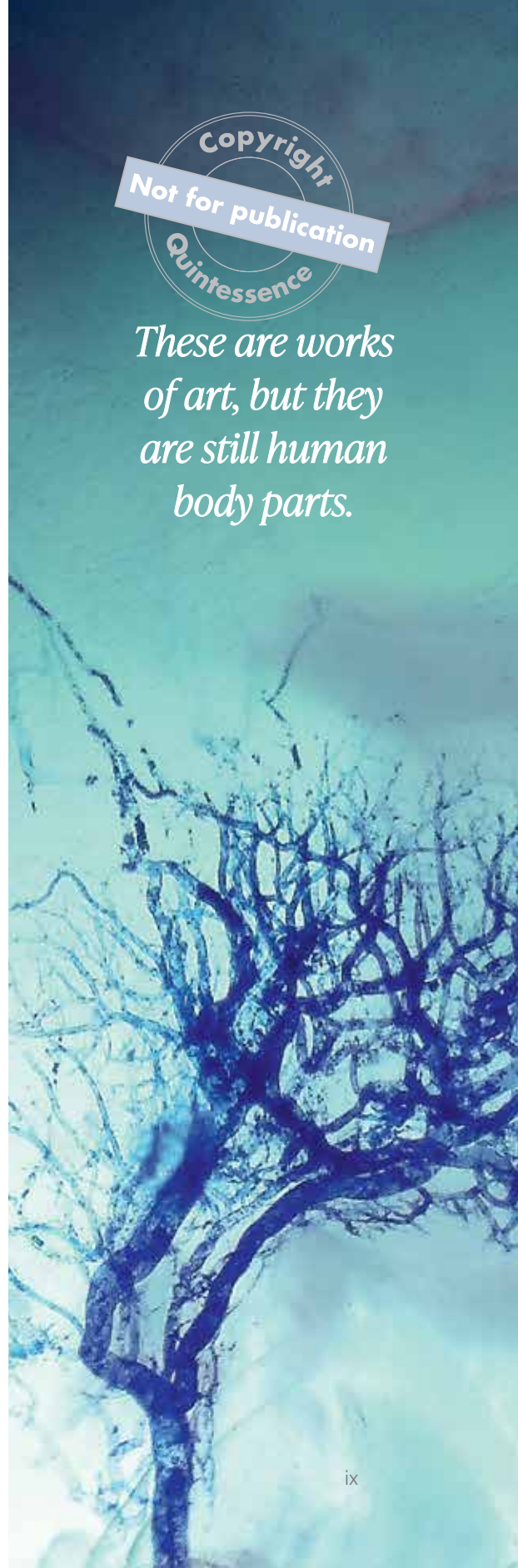

Thus far, all of my research has taken place in the confines of my privately owned dental office. I have paid for all of the supplies with my own personal money. I have accomplished all of the work, results, and innovation in photography techniques completely on my own, unassisted by any outside source. In order to gain a quick volume of samples, specimens were gratefully acquired from oral surgeons and oral surgery departments. I have in no way, fashion, form, or manner profited from the results shown here.

We are missing a lot in dentistry. We extract and discard human teeth like they are trash. No other field of medicine trashes and discards human body parts at the same rate and with the same disregard as found in the field of dentistry. It would be my hope that the anatomical images featured in these pages would change this and set us on a new path, not only to save teeth but save them with a more educated approach than what is prescribed by our current profession.



*These are works  
of art, but they  
are still human  
body parts.*





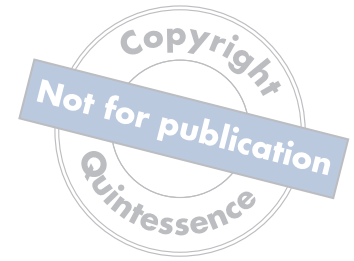# Acknowledgments



I would like to thank Dr Stephanie Roberts Jackson for taking the time to go through this publication systematically and provide amazing feedback. She helped to make this a better and more educationally valuable publication. She was helpful and patient beyond anything I could expect. Dr Roberts Jackson, I always appreciated your realistic and sound perspective from my years in dental school, and I am so pleased to know that you are still that amazing person more than 20 years later. Thank you!



# Introduction



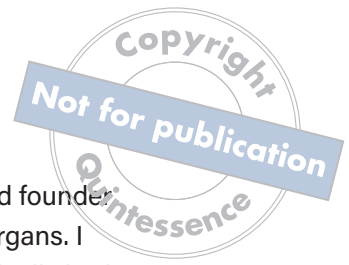"Nobody can outwork me, but then again what I am doing doesn't feel like work."

—Sammy Hagar

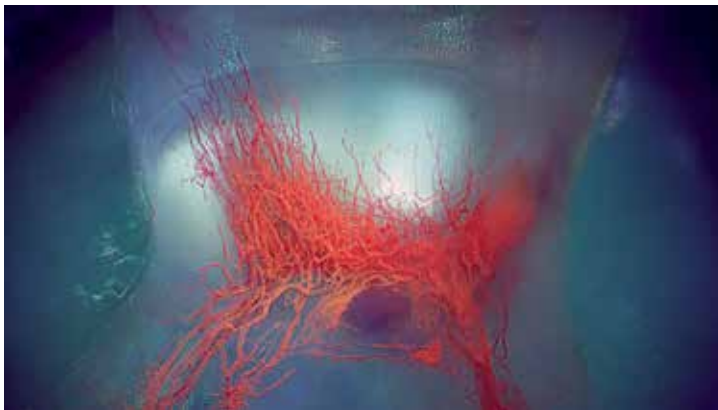
This compilation represents almost two decades of a journey in curiosity and amazement. It has been an absolute privilege to be guided to this path. Progress through continued failure is the only explanation for the results that have been compiled in this book. "Fail fast; fail forward" was my key quote and mantra. Failure became so beneficial that I found myself almost unable to wait for the next experiment to mess up. It was with deep, calculated observation of patterns and the next available aberration that brought me forward to the next breakthrough. I have literally not worked a day of my life on this project. It has all been energy based in the pure joy and amazement that I have found in the discovery of human anatomy and the associated revealing processes and history of diaphanization.

There are no methods revealed in the context of this publication. The methods have not been written down or stored.

There is not a lot of information available on the vascularity and nerve distribution within a human tooth. Most—if not all—pictures of the vascularity and innervation of the human pulp are artist-generated depictions of what they "believe" or even "wish" is inside our teeth. Other documentations are rare and potentially not easily repeated. Most others are on animal specimens other than humans. There is certainly more than we think hiding inside each and every single tooth. There are literal miles of blood vessels and structures that are not well documented. Given the lack of actual documentation, the structures, functions, and limitations of these tissues are not even close to being understood. Histologic sections slice and dice through any potential 3D rendering, which limits our understanding. It has been estimated that if all the blood vessels in an adult were laid out in a single line, they would go around the earth four times. My guess is that this publication increases that number significantly.



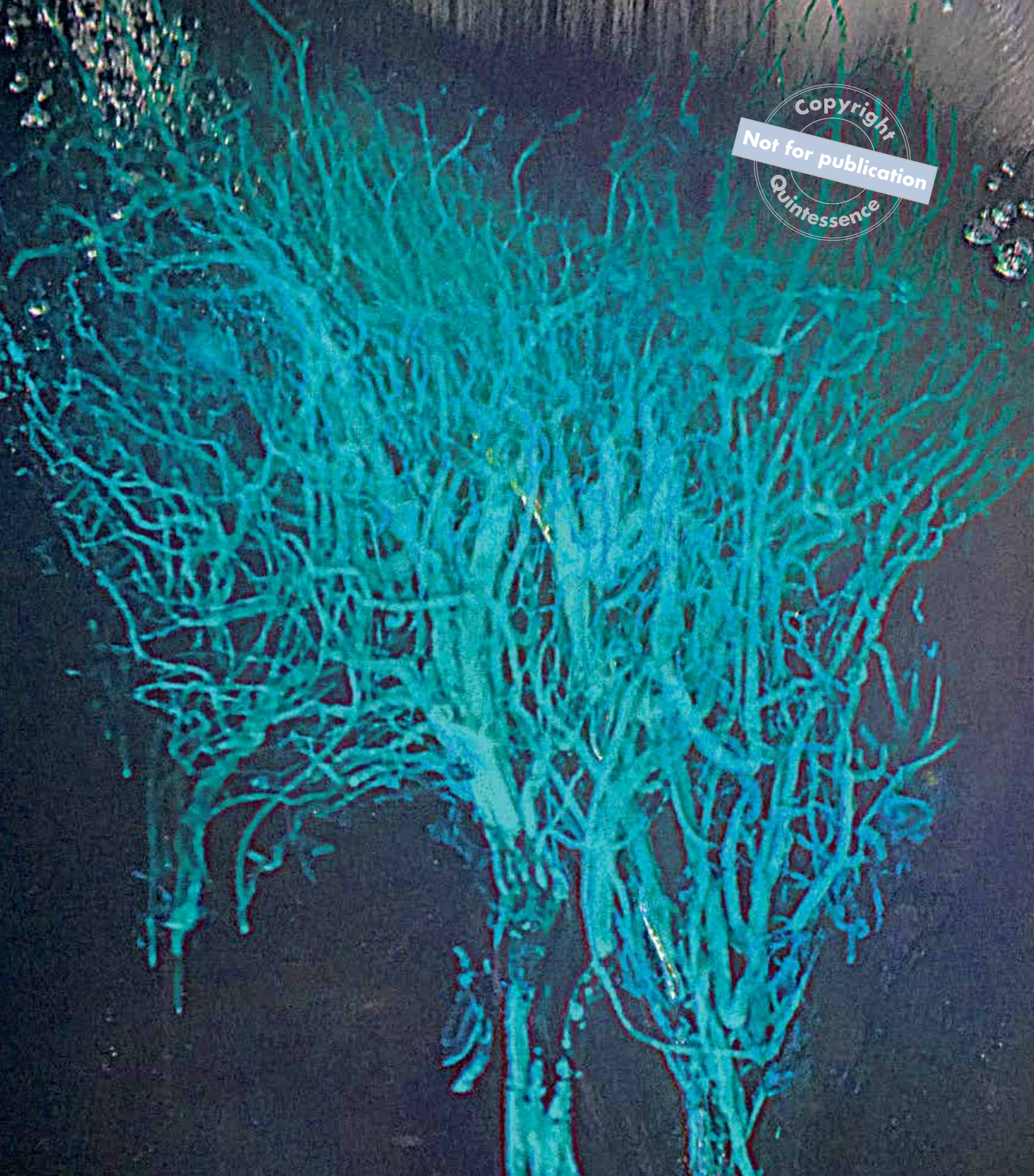
Diaphanization has been around for a long time. Werner Spalteholz is the denoted founder and father of all methods of making transparent whole tissue sections or entire organs. I studied in depth his method of diaphanization for whole organs and then scientifically broke down each step over 18 years until I understood every single nuance of every single step. With that, I was able to develop faster and more definitive methods than previously used. Human teeth pose a very unique and frustrating problem in that they are a mineral (enamel), then a combined mineral and tissue (dentin), and then a tissue (pulp). The dental pulp is an amazing and complex structure, as you will appreciate fully in the pages of this text, and it has been an honor to witness its grandeur, live and in person.



#### THE COVER IMAGE

This image is an extracted mandibular first molar from a person who is about 55 years old. This photograph demonstrates the internal vascularity and vascular distribution within the pulp chamber of that tooth. Specifically, the focus is on the mesial buccal pulp horn. This was photograph #503 of a series acquired over a 2-week period of working with this sample. I would not consider myself a photographer. Through the microscope, I could see the details you can see in this photograph, but I struggled to get the camera to attain the details shown in the final picture. Perimeter lighting via the aid of three prisms and continued experimentation with various light sources finally allowed the camera I used to capture what is shown. To say the least, it is a complete honor to be able to present this to the world. Minor enhancing and sharpening of the image was performed in a photo-editing program; otherwise, this is a virtually raw image. I have been challenged in the past regarding why I do not use focus stacking of several images to increase the depth of field. The answer is that it has simply been my personal preference to maintain images that are as close to a raw as possible, while highlighting specific aspects.





copyright  
Not for publication  
Quintessence





# 1

## The First Results

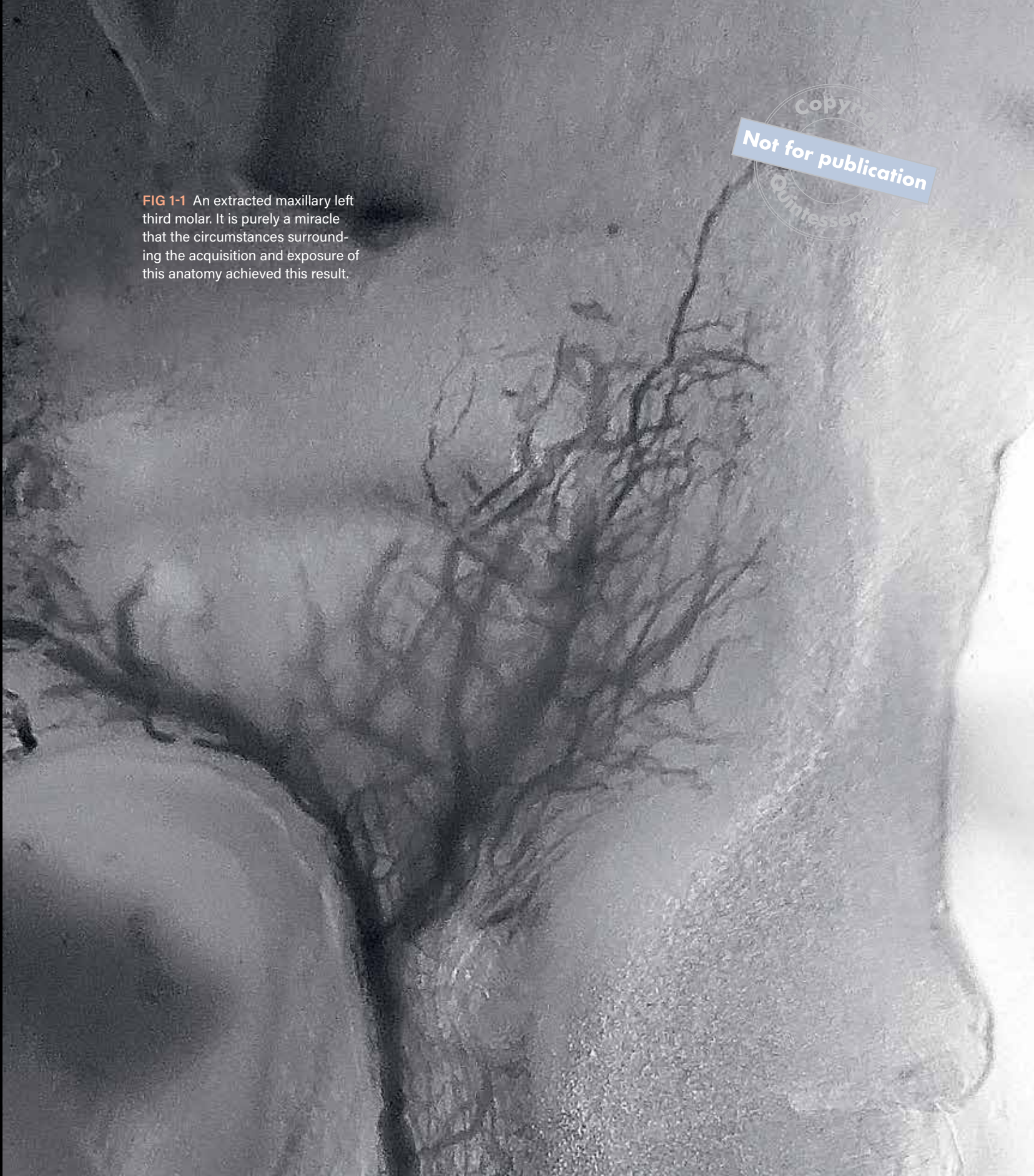
Opportunity and use of the internet are key elements in the discoveries demonstrated in this book. Several years ago, I attended a dental continuing education course on a Saturday in which some intriguing information was discussed. The speaker offered references that did not seem to agree with what was said in the presentation. This caught me by surprise, and I started to check the listed articles more carefully. Oddly enough, the information I found in the references definitively contradicted what was presented in the lecture. This mismatch was my impetus. It sent me searching even further, only to discover products as well as techniques that gave me some amazing ideas that I wanted to put into action in my own lab immediately. I also found by accident key components (almost "household" items) that I was also able to purchase right away and have delivered to my office by Monday morning. All of it came together quickly. Years ago, all of these activities would have taken months or even years, whereas I was able to complete my initial plan and move it forward within hours.

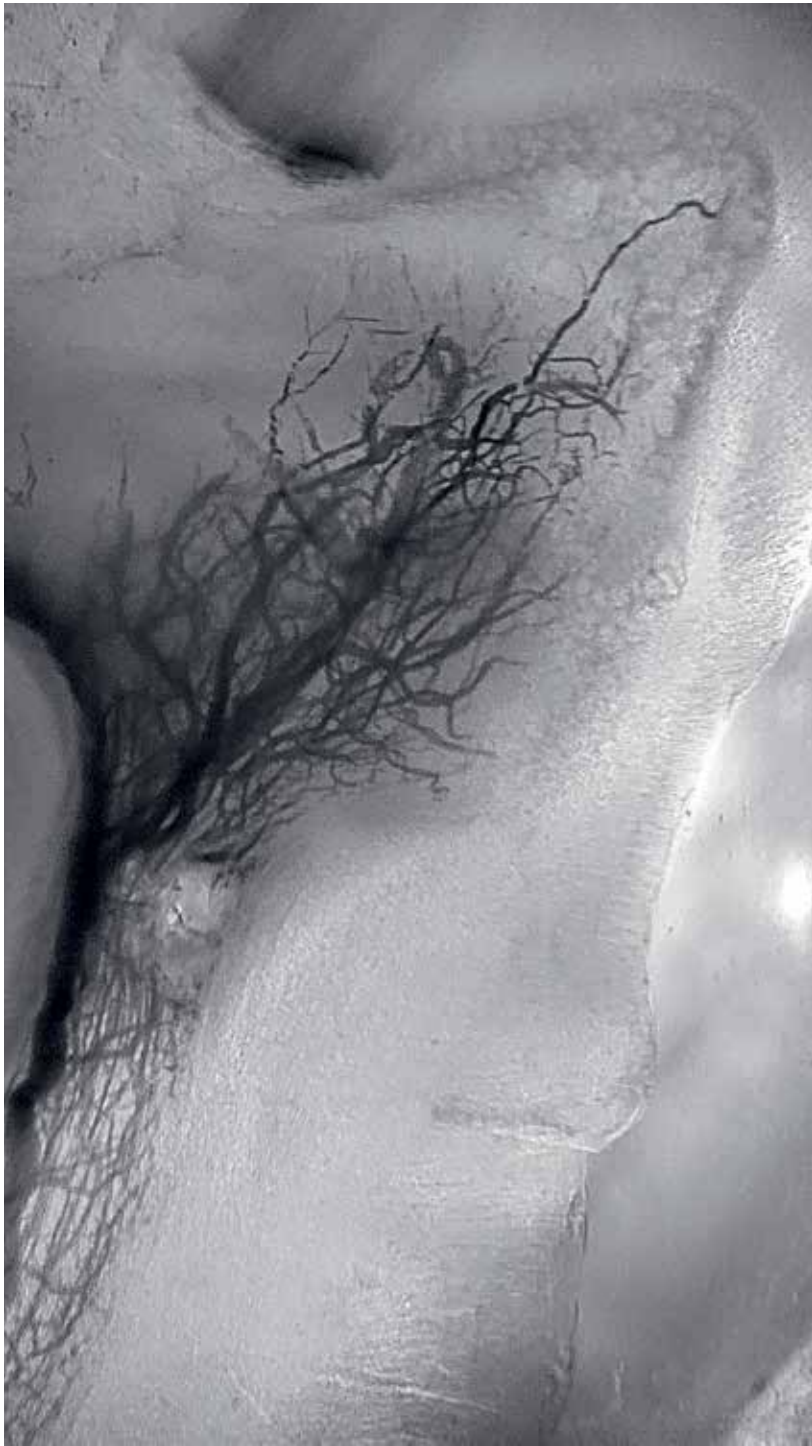A patient was scheduled for an extraction that very Monday morning. I quickly assembled all of the purchased items, and by implementing a few ideas and making some good guesses, I was able to acquire one of the most pristine samples to date, as shown on the recto. A lot of mystery, luck, conjecture, and even an arguable miracle were necessary for me to acquire the pictured result. When the vascularity inside the tooth revealed itself, I sat in total, absolute, and overwhelmed disbelief. A door had been opened, and I saw the possibilities.



copying  
Not for publication  
Quintessen

**FIG 1-1** An extracted maxillary left third molar. It is purely a miracle that the circumstances surrounding the acquisition and exposure of this anatomy achieved this result.

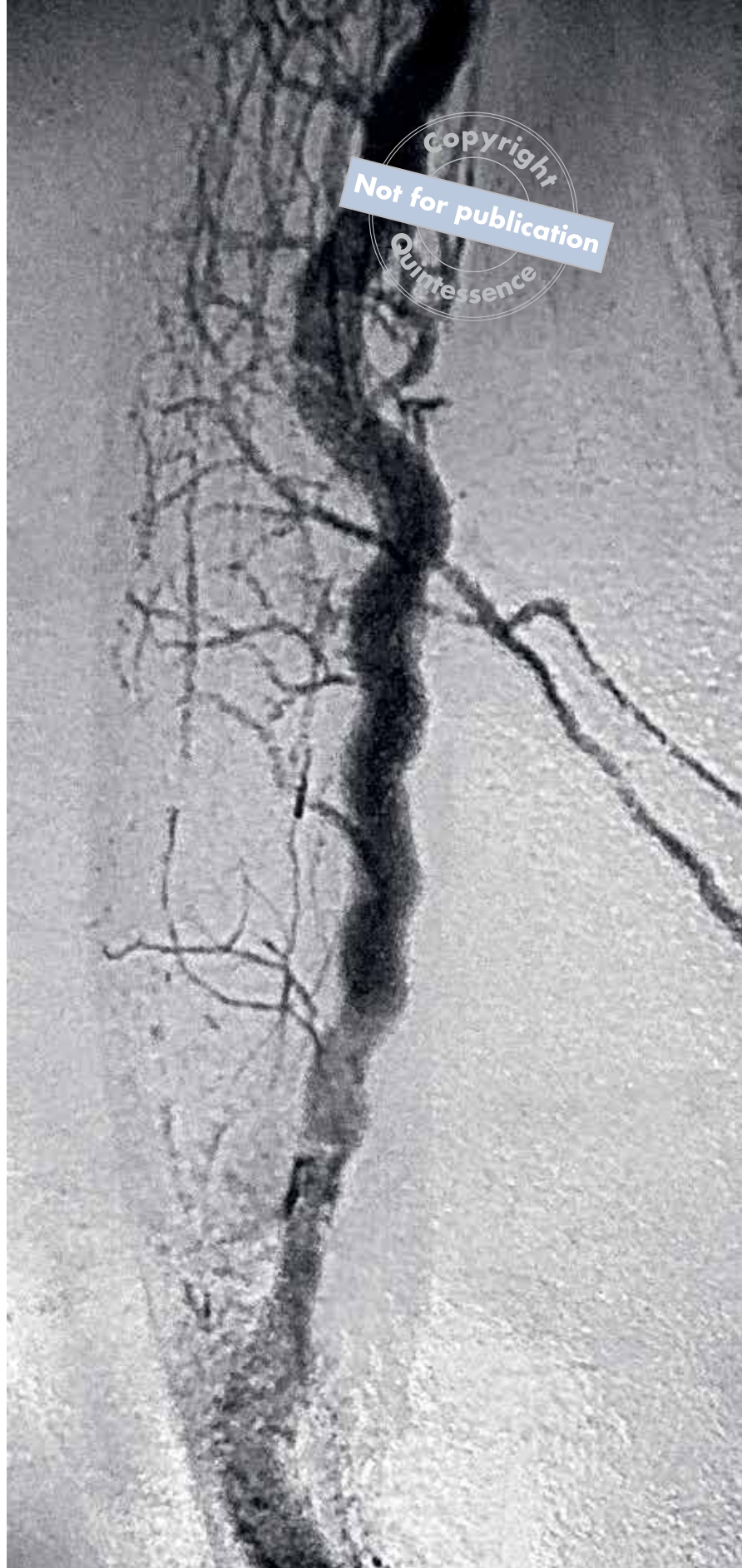




**FIG 1-2** The h... on to the  
right bottom is







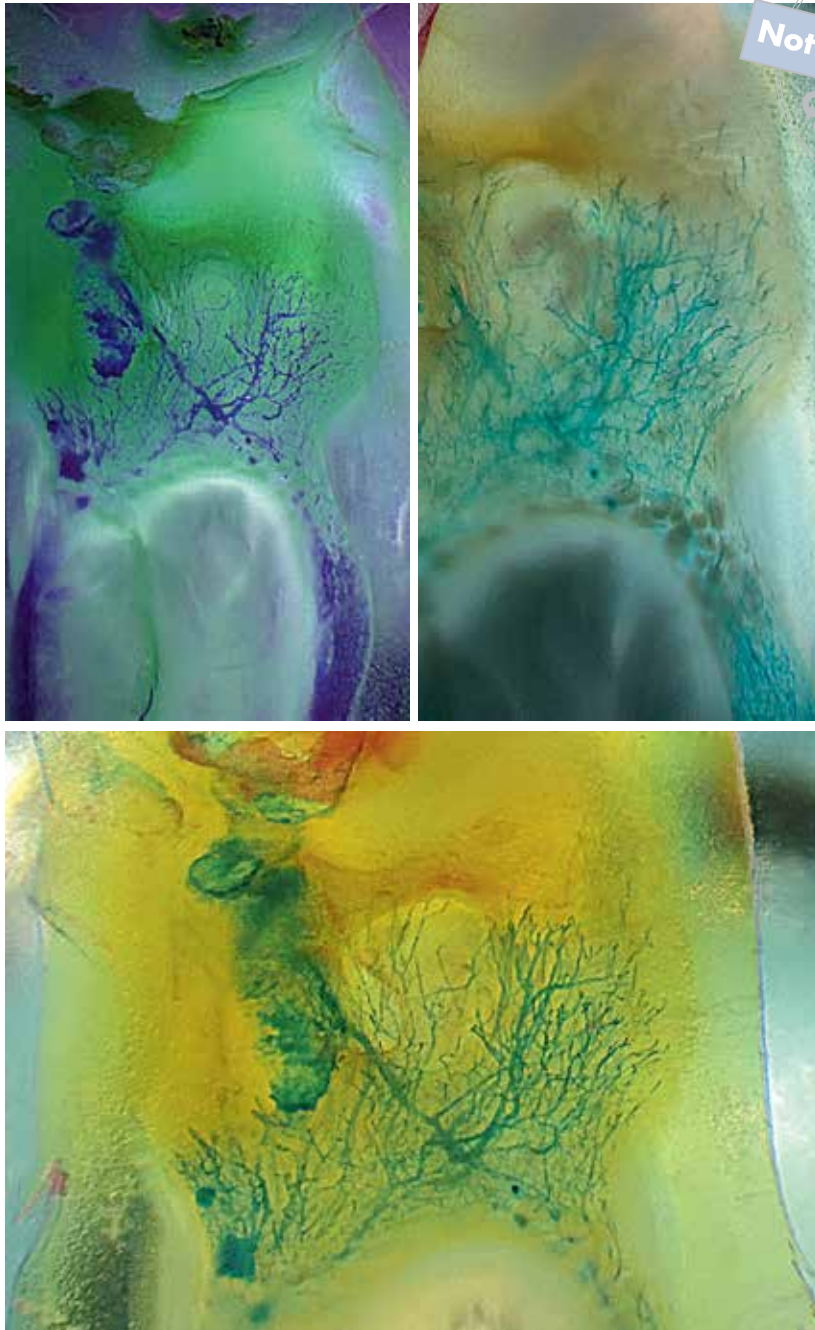
**FIG 1-3** A closer view of the vascularity of the pulp channel system.





An impressive number of denticles are witnessed at the apex. This is the first sample to demonstrate aberrations that have been spoken of and witnessed during the clinical endodontic procedure but never routinely demonstrated or witnessed in histology. Odontoblastic processes decrease in number from chamber to apex, so it is interesting that these denticles are concentrated at the channel orifice.

**FIG 1-4** The second result achieved. A large pulp stone is seen in the center of the chamber.



#### Further Reading

Lo Giudice G, Cutroneo G, Centofanti A, et al. Dentin morphology of root canal surface: A quantitative evaluation based on a scanning electronic microscopy study. *Biomed Res Int* 2015;2015:164065.