

# Peri-implantitis

Stefan Renvert  
Kristianstad - Sweden

Jean-Louis Giovannoli  
Paris - France

# Foreword

As implants have become a widely accepted and – in certain parts of the world – a popular therapy in the restoration of partially and completely edentulous patients, peri-implantitis, i.e. the infection of the peri-implant region will be encountered with increasing frequency. Hence, it is evident that in the future, peri-implant diseases will occupy the practicing dentist more and more.

Consequently, the comprehensive knowledge of the etiology, pathogenesis and epidemiology of peri-implant diseases is of great relevance to address proper protocols for the prevention and therapy of these diseases.

While the aspects mentioned usually get recognition in single chapters in more recent textbooks, the comprehensive review of the topic in a monograph specially devoted to the clinical entity of peri-implantitis is a rare occurrence. Only few authors have so far addressed this important issue of a novel disease pattern that – in part – may be similar to periodontitis and yet may differ from the latter in its susceptibility and pathogenesis.

In that respect, the present monograph provides a comprehensive insight into all aspects of these diseases. Special emphasis is given to the diagnosis of mucositis and peri-implantitis. Probing the peri-implant sulcus on a regular basis is recommended, and evidence for the importance of such clinical monitoring is provided. Emergence of early clinical signs of mucositis reflects the host response to the bacterial challenge. Recognition of such signs may represent the most relevant way of preventing the more advanced level of disease, namely peri-implantitis.

Risk indicators and possible risk factors for the development of peri-implant diseases are carefully selected and discussed on the basis of scientific evidence. This topic usually does not get the necessary attention in other textbook chapters on the issue.

The monograph finally addresses the therapy of both mucositis and peri-implantitis. Clinically efficacious procedures to cope with these diseases are presented. Both non-surgical and surgical approaches are discussed. A chapter on regular supportive care of the implant patient concludes the book. Maintenance was recognized as being the most important aspect for preventing peri-implant diseases, and adequate attention is given to this protocol.

The monograph is highly recommended not only to graduate students and teachers, but especially to the dentist or specialist practicing implant dentistry. The authors are congratulated for a comprehensive and competent review of this emerging field of dentistry that will certainly become one of the major activities in dentistry in the years to come.

*Niklaus P. Lang*

## Acknowledgments

The publication of this book offers us a unique opportunity to express our gratitude to all those who share both our personal and professional life. We first think of our spouses, Pia and Joëlle, and of our children, Helena, Anders, Johanna and Hugo, all of whose love provides the energy for projects such as this book. We think of our collaborators, Christel, Françoise, Isabelle and Karima, of our professional partners, and of all our friends whose loyalty gives us the perseverance to succeed.

We would also like to thank all those who have participated to the production of this book, the publisher Christian Knellesen, the producer Jacques Bonnivard, the designer Laurent Baudchon, Bryn Grisham and Katie Funk for editing this English version, as well as our colleagues Søren Schou, Andreas Stavropoulos and Caspar Wohlfahrt, for generously providing us with histologic material. We thank particularly Noel Claffey for his advice during the process and Niklaus P. Lang for writing the foreword. Finally, we do not forget our referring dentists who provided us with the possibility of treating their patients, as well as the patients themselves, without whom a book such as this would not be possible.

*Stefan Renvert & Jean-Louis Giovannoli*

# TABLE OF CONTENTS

Foreword

Preface

1. Pathogenesis .....	1
2. Diagnosis .....	17
3. Prevalence .....	51
4. Early Peri-Implantitis .....	59
5. Risk Indicators .....	83
6. Treatments .....	131
Appendix .....	189
7. Soft Tissue Conditions .....	209
8. Maintenance .....	235
Index .....	257

## Preface

During the last 20 years dental implants and implants supported suprastructures have become a commonly used alternative to conventional removable and fixed partial dentures. The high survival rate reported in several 10 year follow-up studies has led to a widespread acceptance and use of dental implants. Indeed the indications for implant placement have widened because of the development of new treatment techniques. In most of the early clinical studies, the quality of the therapeutic outcomes was assessed in terms of survival rates, referring to the physical presence of the implant in the oral cavity. At the outset, authors were paying more attention to the mechanical incidents explaining implant loss than to the biologic causes. Nowadays, we are witnessing a growing awareness of the role played by the health status of peri-implant tissues on the survival of implants. Although the general impression of implant therapy is that the success rate is high, infections defined as peri-implant mucositis and peri-implantitis are commonly found. As with periodontal diseases, peri-implant mucositis and peri-implantitis are recognized as inflammatory diseases of infectious origin, ultimately leading to loss of bone supporting the implant. Peri-implant mucositis is defined as an inflammatory lesion limited to the surrounding mucosa, whereas peri-implantitis also affects the supporting bone. The control of these diseases is essential for all clinicians who desire to obtain long-term positive results with implants and for all those interested in the prevention and the treatment of oral infections.

According to available epidemiologic data, it appears that one out of five patients will develop peri-implantitis over time and that peri-implant mucositis is a very common phenomenon among implant patients. At present there are limited scientific data on the treatment of peri-implant diseases, and most treatment modalities are adapted from those used for the treatment of periodontal diseases; the primary therapeutic approach being aimed at controlling infection. This may involve adjustment of prostheses to allow for proper oral hygiene and professional removal of the biofilm and hard deposits from the implant surface. In advanced peri-implantitis cases a surgical approach may be necessary to gain access to disrupt and remove the biofilm. If appropriate at such a surgical intervention, regenerative treatments to regain the lost bone may also be performed. At present, therapeutic interventions in peri-implantitis cases are, in many instances, based on clinical experience as robust clinical data are lacking in many areas. However, research activity in this field is very high, and new data are continuously produced with the expectation of clearer guidelines for the treatment of these conditions in the future.

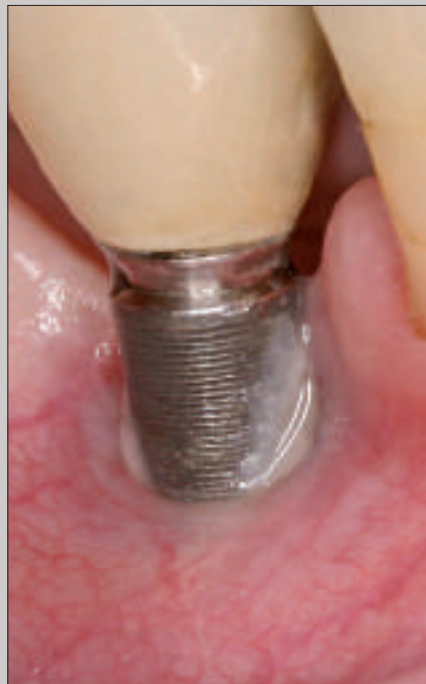For practitioners who wish to avoid peri-implant mucositis and peri-implantitis, the early diagnosis of problems using a periodontal probe and the evaluation of the health status around implants is essential. Early diagnosis allows for early intervention that, as highlighted in this book, is very effective. If early signs are overlooked the treatment options become both more complicated and less predictable.

*Stefan Renvert & Jean-Louis Giovannoli*

# Pathogenesis

## Microflora

The concept that microorganisms are essential for the development of infections around dental implants is well supported in the literature<sup>7-7</sup> (Fig 1-1). Shortly after implants have been placed, glycoproteins from the saliva adhere

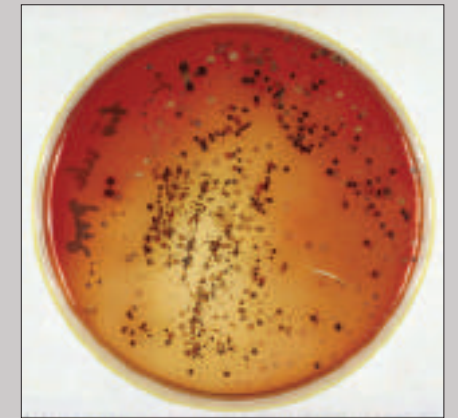


**Fig 1-1** Dental plaque on an exposed implant surface.

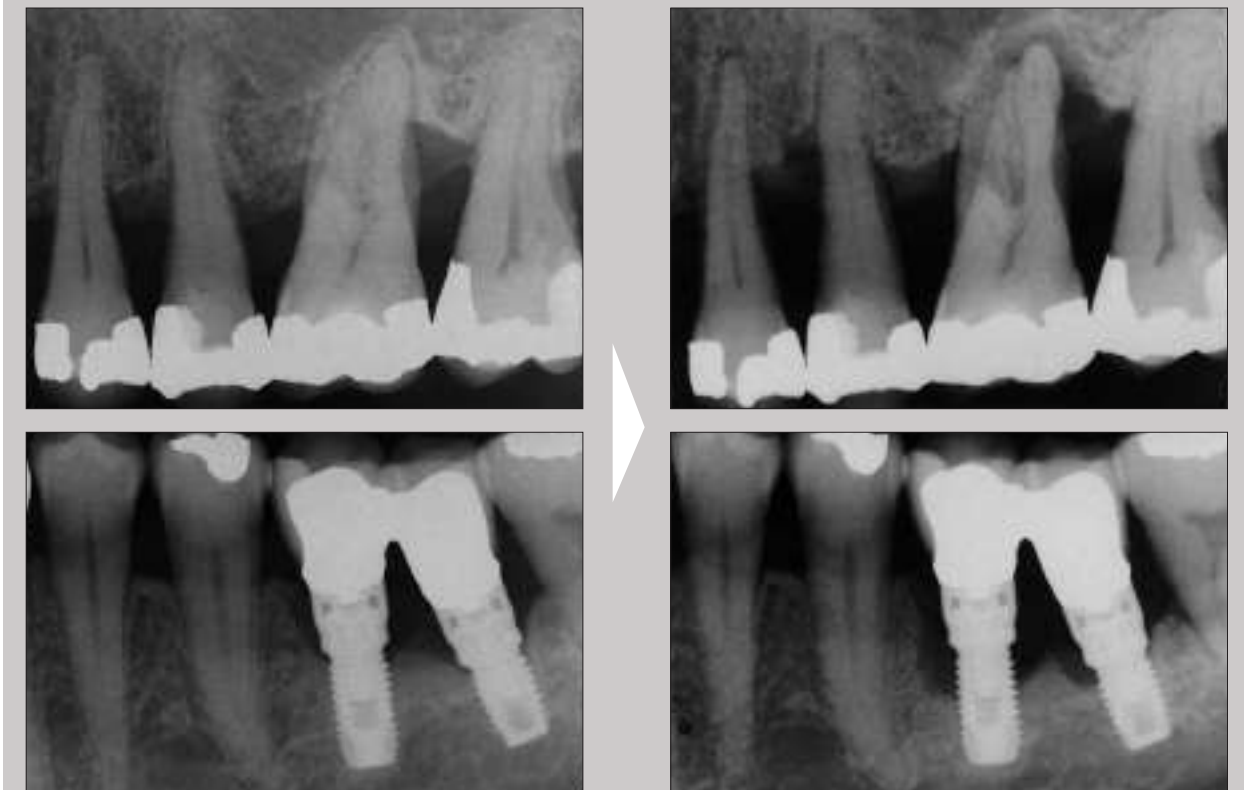
to the exposed titanium surfaces. The glycoprotein layer is then colonized by microorganisms.<sup>7-10</sup> A subgingival microbiota dominated by *Peptostreptococcus micros*, *Fusobacterium nucleatum*, and *Prevotella intermedia* is established.<sup>8</sup> Peri-implant diseases are associated with a predominantly gram negative anaerobic microflora similar to that associated with periodontitis. High levels of peri-odontal pathogens including *Aggregatibacter actinomycetem-comitans*, *Porphyromonas gingivalis*, *Prevotella intermedia*, *Tannerella forsythia*, and *Treponema denticola* have been associated with peri-implantitis<sup>11</sup> (Fig 1-2). Studies have also suggested that

peri-implant disease microflora may include *Fusobacterium nucleatum* and *Actinomyces* species as well as *Staphylococcus aureus* and enterococci.<sup>12,13</sup> *S aureus* has been observed to colonize other foreign bodies; complications may result, for example, at the site of hip transplants. Titanium favors colonization with *S aureus*, which is commonly found around dental implants.<sup>14-16</sup>

It has been suggested that the microflora present in the oral cavity at the time of implant placement may influence the developing biofilm on the implants. Accordingly, periodontal pockets surrounding teeth may act as a reservoir for microorganisms that colonize the newly inserted implants<sup>6,17</sup> (Fig 1-3).

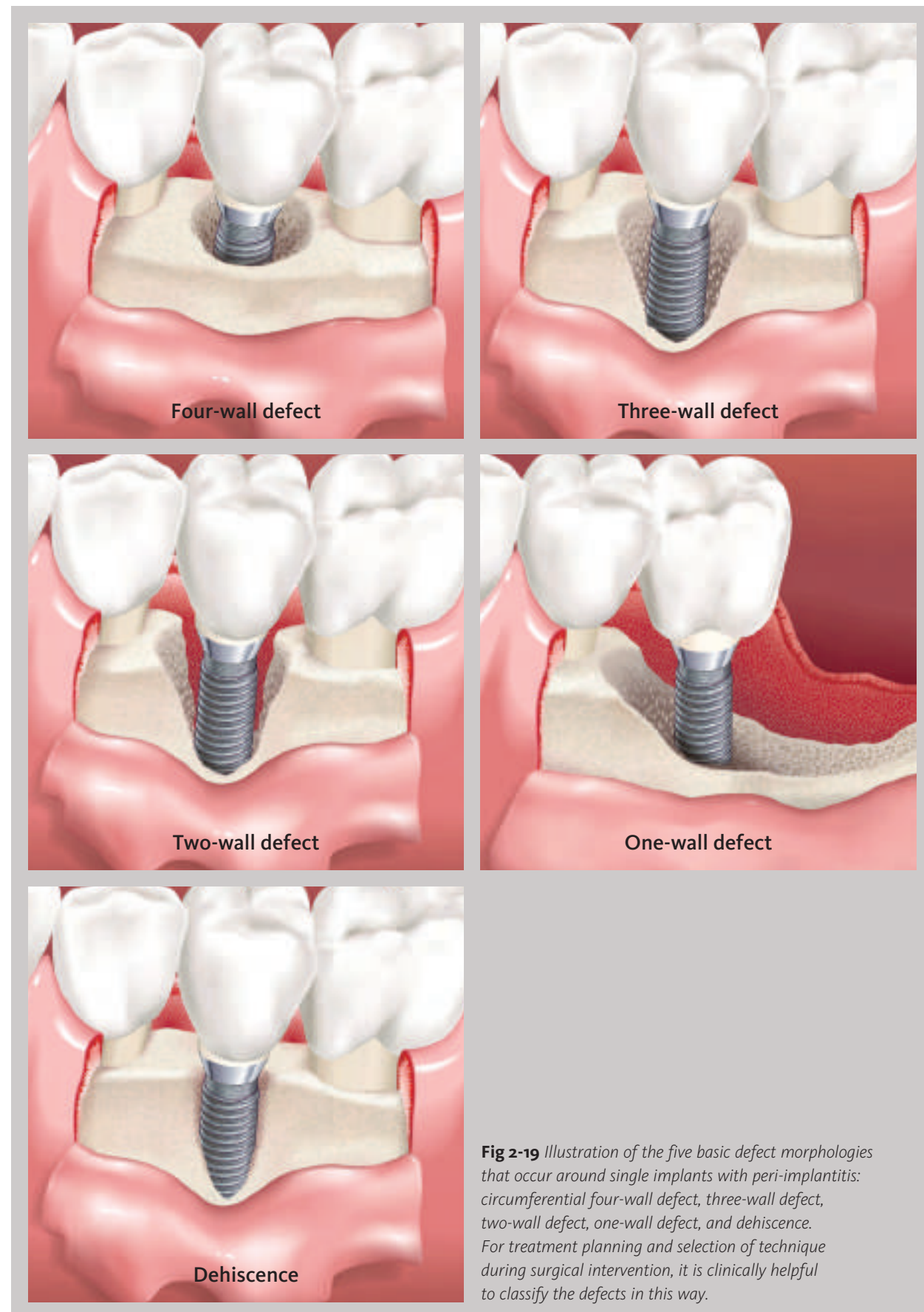


**Fig 1-2** Growth of anaerobic microorganisms on an agar plate.

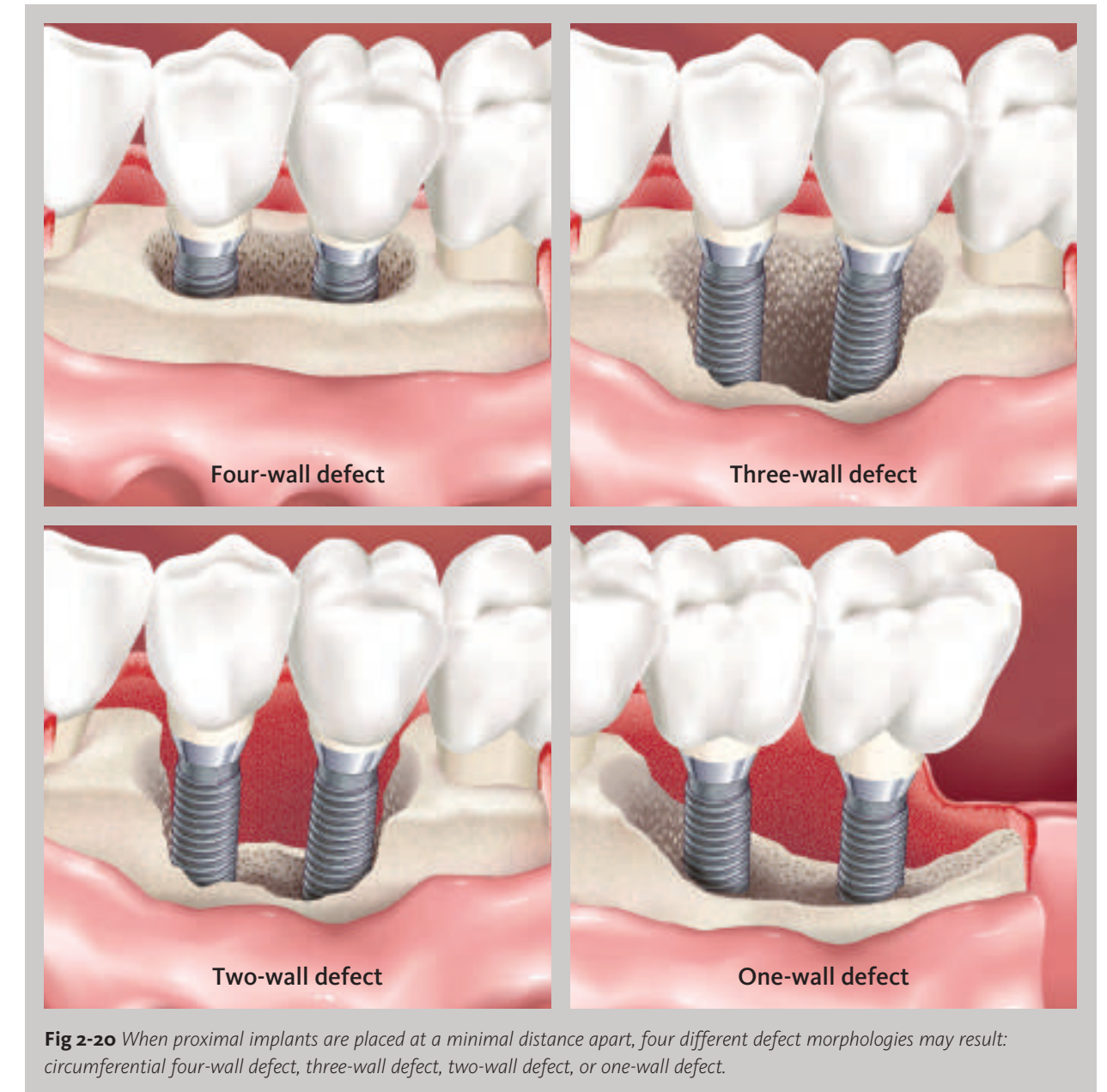


**Fig 1-3** Radiographs from a patient with periodontal disease in which implants were placed. Progression of disease is verified by resorption of bone around both teeth and implants after 3 years.

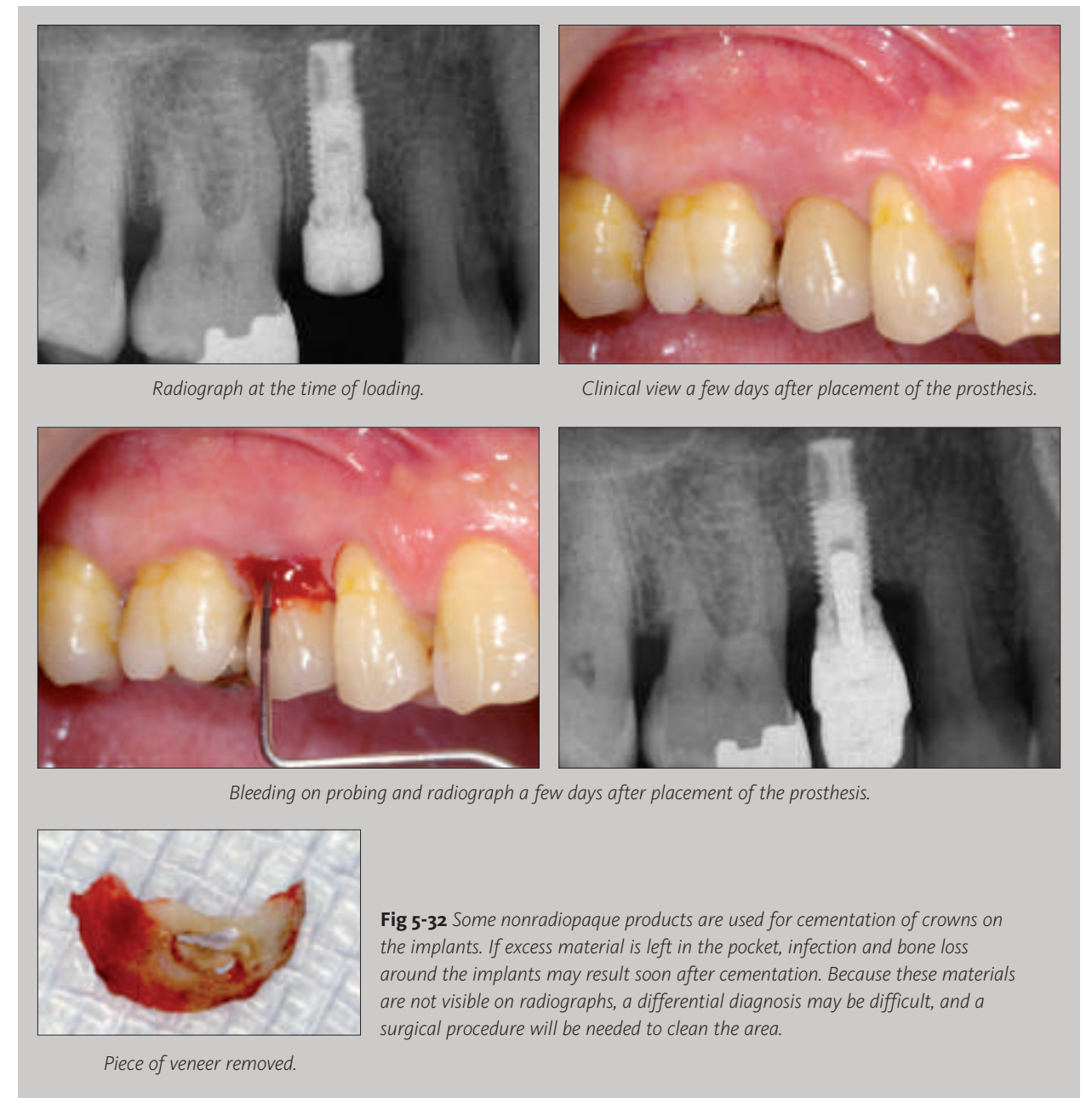
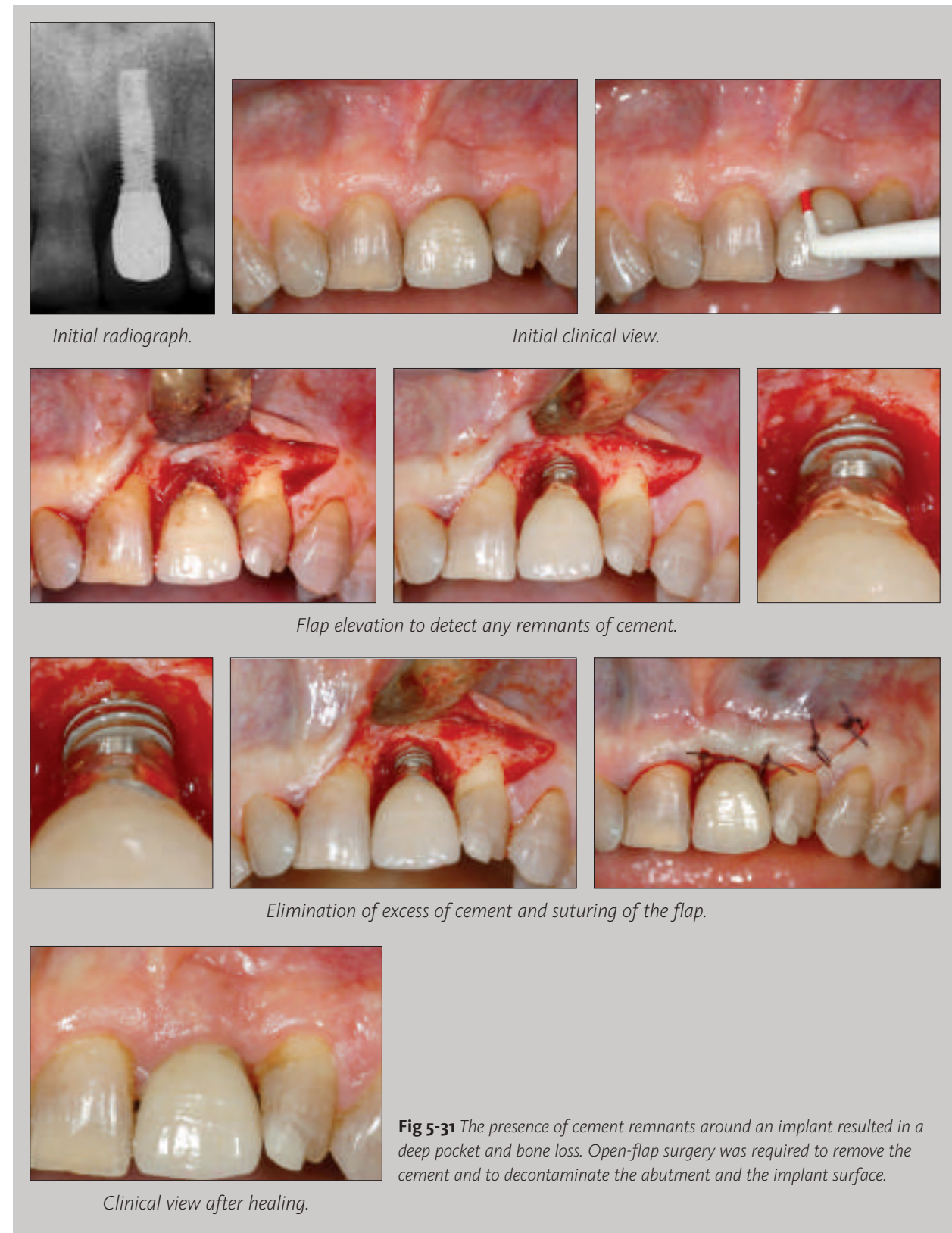



The same classifications may be used when the implants have been placed at a minimal distance from each other, and the proximal bone between implants is totally resorbed (Fig 2-20). When that happens, the defects are more significant, with no bony wall between the two proximal defects; however, these defects could still be classified as (1) circumferential craterlike four-wall defects, (2) three-wall defects, (3) two-wall defects, or (4) one-wall defects.

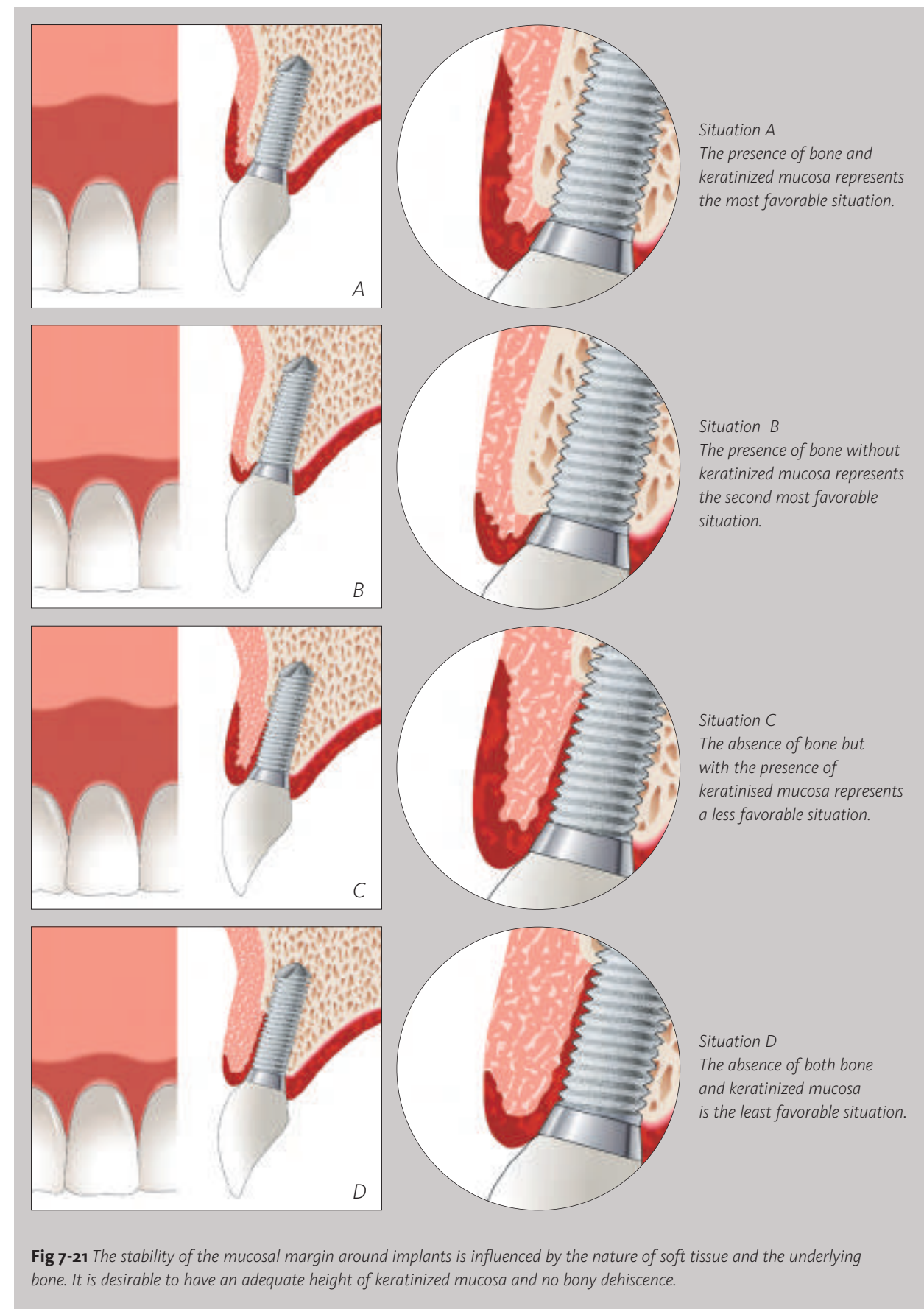






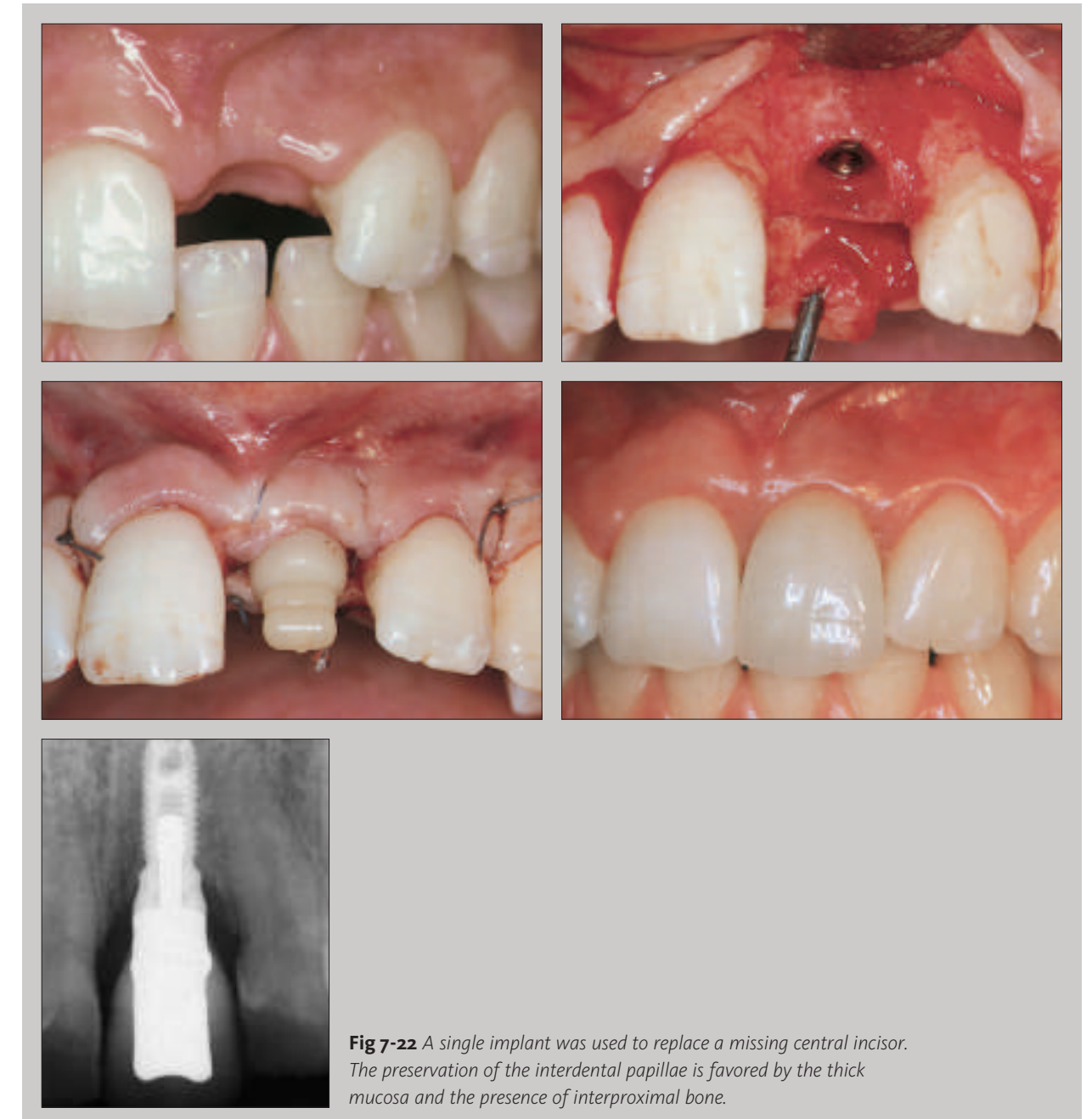
If guided bone regeneration is performed at the time of implant placement, granules of bone substitute may become encapsulated in the soft tissue and act as a foreign body. This situation may result in peri-implantitis, necessitating a surgical procedure to eliminate the nonintegrated granules and granulation tissue (Fig 5-33).





The biotype primarily affects the development of buccal recession and does not affect interproximal papillary heights.<sup>22</sup> The papillary level around single-tooth implants in the anterior maxilla is affected by the interproximal bone crest level of the adjacent teeth, whereas the facial marginal mucosal level is affected by peri-implant tissue biotype, level of the facial bone crest, angle of the implant fixture, level of the interproximal bone crest, depth of implant platform, and level of first bone-to-implant contact<sup>23</sup> (Fig 7-22).

In the anterior region, the techniques used in periodontal plastic surgery can be used to improve the esthetic results around implants, but in the presence of a bony dehiscence, the deficient buccal bone should also be reconstructed.



## Index

### A

---

Accessibility: 86, 102, 105, 125, 133, 137, 150, 212, 223, 239, 241, 243  
 Acute infection: 36, 42  
 Adhesion: 56, 110, 111  
 Air abrasive: 71, 145, 146, 149, 253  
 Alcohol consumption: 101  
 Anaerobic bacteria: 2, 90, 108  
 Antibiotics: 63, 64, 72, 133, 146, 147  
 Antiseptics: 133, 136, 139, 141, 254  
 Autogenous bone: 72, 77, 156, 185

### B

---

Bacterial sampling: 36, 247  
 Bacterial translocation: 3, 107, 110  
 Biofilm: 11, 114, 132, 133, 145, 148  
 Biotype: 225-227, 229, 232  
 Bleeding on probing: 19, 20, 21, 26, 31, 36, 52, 68, 86, 125, 139, 140, 142, 146, 211, 213  
 Bone harvesting: 156  
 Bone remodeling: 12  
 Bone substitute: 62, 70, 72, 77, 121, 152, 156, 157, 162, 177, 185

### C

---

Calculus: 239, 247, 252  
 Cementum: 119, 121, 122  
 Collagen fibers: 6, 9  
 Connective tissue: 6, 9, 10  
 Connective tissue graft: 227  
 Contamination: 36, 56, 60, 64, 107, 123, 148, 174  
 Carbon-fiber curette: 252  
 Cytokines: 10, 98, 100

### D

---

Decontamination: 71, 77, 147-150, 177  
 Defect four wall defect: 31, 32, 33, 156, 157, 177  
 Defect one wall: 31, 32, 33, 157  
 Defect three wall defect: 31, 32, 33, 157, 162  
 Defect two wall defect: 31, 32, 33, 157, 175  
 Dehiscence: 28, 31, 32, 152, 157, 166, 227-229, 232  
 Dental floss: 136, 138  
 DNA probe: 36  
 Drainage: 77  
 Dysfunction: 244, 248

### E

---

Early mucositis: 61  
 Early peri-implantitis: 60, 66, 69, 72, 80  
 Endodontic pathology: 64, 66, 70, 123, 124, 174, 248  
 Epulis: 46  
 Excess endodontic material: 65, 66

### F

---

Fibroblast: 11  
 Fistula: 68  
 Foreign body: 85, 119, 121, 122, 135  
 Free gingival graft: 166, 167, 216, 223  
 Full mouth extractions: 53, 108, 109  
 Functional loading: 18, 20, 27, 31, 67, 236, 247

### G

---

Generalized peri-implantitis: 43  
 Genetic trait: 85, 98  
 Glycoproteins: 2  
 Glycosylated hemoglobin: 100

### H

---

History of periodontitis: 84, 85, 90, 95, 98, 100, 107, 110  
 Horizontal bone loss: 31, 34, 152, 174  
 Hydrogen peroxide: 69, 71, 150, 185, 254  
 Hyperplasia: 43, 45, 225

### I

---

Immediate implant placement: 66  
 Implant fracture: 13, 38, 39, 236, 247  
 Implant survival: 18  
 Implant-abutment connection: 115, 118, 119  
 Inflammatory cells: 9, 10, 11  
 Inflammatory infiltrate: 8, 9, 11  
 Inflammatory lesion: 7, 9  
 Interproximal brushes: 136, 138, 149, 237, 239, 242  
 Irrigation: 139, 254

### J

---

Juxta-implant lesion: 68

### K

---

Keratinized mucosa: 6, 8, 124-126, 166, 212-213, 216, 222, 224-228, 232

**L**

Laser: 133, 143, 146, 149  
 Level of insertion: 111  
 Link porcelain gingiva: 87, 242  
 Loss of osseointegration: 12, 13, 39, 40  
 Lymphocyte: 8, 9, 11

**M**

Maintenance program: 53, 86, 97, 134, 247, 248  
 Marginal contour: 211  
 Marginal stability: 224, 226, 227, 229  
 Membrane: 62, 72, 74, 77, 152, 156, 157, 162, 166  
 Metabolic control: 100, 101  
 Microflora: 2, 56, 84, 132  
 Mobility: 34, 39, 40, 69, 96, 125, 211  
 Monocyte: 11  
 Mouthrinses: 139, 141

**N**

Necrotizing: 46  
 Nighguard: 244  
 Nonosseointegrated implants: 67

**O**

Occlusal overload: 12, 13, 39, 247  
 Oral hygiene: 12, 55, 61, 69, 85–89, 90, 97, 101, 102, 105, 133–139, 147, 185, 212, 223, 237, 238, 241, 243, 247  
 Orthodontic retainer: 244  
 Osseointegration: 12, 18, 27, 34, 39, 55, 60, 67, 72, 123, 133, 216, 236  
 Osteoclast: 11  
 Overdenture: 137, 242

**P**

Papilla: 229, 230  
 Parafunction: 244, 248  
 Patient compliance: 86, 141, 142, 237  
 Peri-implant mucosa: 19, 20, 43  
 Periodontal patients: 4, 54–56, 62, 63, 87, 90, 94, 97, 101, 109, 116, 137, 237, 244, 248, 254  
 Plasma cells: 9, 11  
 Plastic curette: 252

Plastic probe: 22, 48  
 Platform switching: 118  
 Pocket depths: 6, 21, 25, 48, 85, 93, 110–112, 117, 118, 134, 140–143, 146, 150, 151, 162, 173, 185  
 Polymorphonuclear leukocytes: 9, 11  
 Prevalence rates: 52  
 Primary failure: 18  
 Progression, disease: 24, 26, 36, 42, 85, 113, 125, 148, 173, 216  
 Proximal endodontically treated tooth: 64

**R**

Recession: 19, 20, 140, 162, 212, 224–229, 231, 232  
 Reosseointegration: 80, 184, 185  
 Reservoir: 3, 107, 109  
 Retention bar: 242, 243  
 Retrograde peri-implantitis: 60, 66, 69, 70, 77, 80  
 Risk indicators: 84, 98  
 Rough implant surface: 55, 56, 85, 110–114, 133, 135, 142, 184

**S**

Saline: 148, 150  
 Secondary failure: 18, 19, 38  
 Smoking habits: 12, 55, 85, 95–97, 101, 248  
 Stress: 101  
 Submerged technique: 182–184  
 Suppuration: 19–21, 31, 42, 48, 54, 68, 86, 119, 146  
 Susceptibility: 84, 107

**T**

Technical complications: 12, 13, 38, 236, 244  
 Terminal peri-implantitis: 34, 35, 40, 178  
 Titanium probe: 22  
 Traction: 211, 212, 216  
 Transmucosal part: 85, 110, 111, 113, 140

**U**

Ultrasonic devices: 135, 142

**W**

Width of marginal mucosa: 125, 211